ORTHOPAEDICS

General Orthopaedics — Questions

1. Increase Callus or Cartilage formation is seen in :

A. Rigid immobilization
B. Necrosis of bone ends
C. Increase mobilization
D. Compression plating

2. Adult bone trabeculae are differentiated from fetal bone trabeculae by the presence of

A. Harversian system
B. Lamellar structure
C.Certain special staining characteristics
D. Different types of bone cells in each

3. The tensile strength of a bone is due to:

A. Strands of collagen
B. Hydroxyapatite crystals
C. Periosteum
D. Metaphysis

4. Callus formation is seen between what duration of fracture healing:

A. 0-2 weeks
B. 2-4 weeks
C. 4-12 weeks
D. 12-16 weeks

5. Most metabolically active part in bone is

A. Cortical bone
B. Cancellous bone
C. Periosteal surface
D. Endosteal surface

6. Wolff's law states that:

A. If a bone is continuously subjected to a particular stress it will adapt to become stronger to resist that loading
B. Only diaphysis allows longitudinal growth in childhood
C. Any infection not showing periosteal reaction within 1 week of symptoms can be ruled out to be osteomyelitis
D. Angular deformities will progress till the closure of physis

7. Bone resorption is inhibited by:

A. Parathyroid hormone
B. Thyroid hormones
C. Cortisol
D. Estrogen

8. Rate of mineralization of newly formed osteoid can be estimated by the following:

A. Von kossa staining for calcium
B. Alzarin red stain
C. Labelled tetracycline
D. Immunofluorescence

9. Bone apposition is best seen in

A. Endochondral ossification
B. Osteoblastic activity in howship's lacunae
C. Subperiosteal cambium layer
D. Osteoblastic activity at the area of stress

10. Regarding bone remodelling, all are true except:

A. Osteoclastic activity at the compression site
B. Osteoclastic activity at the tension site
C. Osteoclastic activity and osteoblastic activity are both needed for bone remodeling in cortical and cancellous bones
D. Osteoblasts transforms in to osteocytes

11. Diagnostic sign of a fracture:

A. Abnormal mobility at fracture site
B. Pain at the fracture site
C. Tenderness
D. Swelling

12. The most common sign of fresh fracture is:

A. Crepitus
B. Bony tenderness
C. Deformity
D. Abnormal mobility

13. A child falls from a chair. Complains of pain in the mid leg. No visible deformity. He is unable to bear his weight on standing. What is the diagnosis?

A. Oblique fracture
B. Spiral fracture
C. Comminuted fracture
D. Fracture of epiphysis

14. All of the following factors facilitate non- union except:

A. Hematoma formation
B. Periosteal injuries
C. Absence of nerve supply
D. Chronic infection

15. Delayed union of fracture of a bone following a surgical treatment may be due to:

A. Infection
B. Inadequate circulation
C. Inadequate mobilization
D. All of the above

16. Which of the following injuries can be classified as Gustilo-Anderson Grade III injuries?

A. Open fracture with clean wounds less than 1 cm long
B. Open fractures with a laceration more than 1 cm long usually up to 10 cm, with extension tissue damage, flaps or avulsions
C. Open segmental fractures, open fracture with extensive soft tissue damage
D. Compartment syndrome with an open fracture

17. Open fracture in children is managed by:

A. Debridement
B. External fixation
C. Open reduction and Internal fixation
D. Intramedullary nail

1. c	2. b	3. a	4. c	5. d	6. a	7. d	8. c	9. c	10. a	11. a	12. b	13. b	14. a
15. d	16. c	17. a											

18. A patient with gun shot wound in tibia presents with comminuted fracture tibia with 2 cm wound. This belongs to what grade of Gustilo-Anderson classification of open fractures:

A. Grade 1
B. Grade 2
C. Grade 3a
D. Grade 3b

19. Vascular repair to be done in which Gustilo-Anderson type:

A. IIIC
B. I
C. II
D. IIIb

20. Hypertrophic non- union following a fracture, most appropriate treatment would be:

A. Stabilisation
B. Bone grafting
C. Stabilisation and bone grafting
D. None of the above

21. Following are immediate complications of fracture:

A. Vascular ischemia
B. Malunion
C. Compartment syndrome
D. Avascular necrosis

22. Fracture healing is affected by all except:

A. Osteoporosis
B. Infection
C. Poor blood supply
D. Soft tissue interposition

23. Factors affecting bone healing are all except:

A. Age
B. Sex
C. Vascularity
D. Comminution

24. Initial stage of clinical union of bone is equivalent to:

A. Callus formation
B. Woven bone
C. Hematoma formation
D. Calcification only

25. The most common cause of non union is:

A. Infection
B. Inadequate immobilization
C. Ischemia
D. Soft tissue interposition

26. Commonest 1st order site for bone grafting:

A. Iliac crest
B. Tibial metaphysic
C. Medial malleolus
D. Femoral condyle

27. Commonest site of Epiphyseal injury in children:

A. Lower end radius
B. Lateral condyle humerus
C. Upper end femur
D. Lower end femur

28. In children, best remodelling is seen in fractures with:

A. Angulation in diaphysis
B. Angulation in metaphysis
C. Rotation in diaphysis
D. Rotation in metaphysis

29. Thomas splint was devised by Sir H.O Thomas:

A. To splint fracture shaft of femur
B. To stabilize cervical spine after trauma
C. For transportation of polytrauma patients
D. For treating tuberculosis of knee

30. Which side of plaster is manipulated for wedging:

A. Anterior
B. Posterior
C. Concave
D. Convex

31. The commonest cause of pathological fracture is generalized affection is:

A. Carcinoma
B. Osteoporosis
C. Cyst
D. All of the above

32. The treatment of choice in pathological fractures is:

A. Internal Fixation
B. Plaster of paris casts
C. Skin traction
D. External skeletal fixation

33. Differential diagnosis of stress fracture:

A. Infection
B. Tumor
C. Neuropathic joints
D. Osteochondritis

34. An army recruit, smoker and 6 months in to training started complaining of pain at postero-medial aspect of both legs. There was acute point tenderness and the pain was aggravated on physical activity. The most likely diagnosis is:

A. Beurger's disease
B. Gout
C. Lumbar canal stenosis
D. Stress fracture

18. c	19. a	20. a	21. a	22. a	23. b	24. b	25. b	26. a	27. a	28. b	29. d	30. c	31. b
32. a	33. a	34. d											

1. C. Increase mobilization

Rigid immobilisation / compression plating acts by primary fracture healing where callus formation is not seen. Necrosis of bone ends will lead to non-union. Micromotion at fracture site helps in callus formation.

2. B. Lamellar structure

Lamellar bone pattern is one that is present in normal adult compact as well as cancellous bones

3. A. Strands of collagen

The tensile strength of bone is due to stress oriented collagen fibres which make up the organic component of the intercellular matrix of bone.

4. C. 4-12 weeks

Stage of callus formation – callus is the earliest sign of fracture healing and is visible on xray by 3 weeks. It is not seen in 2nd week, and thus option C) 4-12 weeks is the best pic.

5. D. Endosteal surface.

Bone formation is more than bone resorption on the periosteal surface and bone resorption is more than bone formation on the endosteal surface, and it is metabolically most active part of bone.

6. A. IF a bone is continuously subjected to a particular stress it will adapt to become stronger to resist that loading

Wolfs law states that in areas of stress / compression thicker lamellar bone is laid (i.e osteoblast are active there) and in areas of tension/ no stress unwanted bone is carved away(i.e osteoclast are more active) to regain normal anatomical shape.

7. D. Estrogen

All other mentioned options has role in mobilising calcium from bones, while estrogen acts to increase bone density.

8. C. Labelled tetracycline

When tetracycline is infused it gets fixed with newly formed mineralised bone giving a specific fluorescence under UV light. Thus when 2 doses of tetracycline is infused in days apart, 2 bands of fluorescence is visible separated by a clear zone which depicts new bone that was formed during the period between the two doses.

9. C. Subperiosteal cambium layer

Adults have mature bone and they grows only by appositional growth. Cambium layer(Inner layer of periosteum) is responsible for appositional growth which contains osteoprogenitor cells. Longitudinal growth, occurs before maturity and is primarily due to cartilage proliferation at the growth plate/ physis, which subsequently mineralizes to form bone.

10. A. Osteoclastic activity at the compression site

During bone remodelling there is osteoclastic activity at the tensile site and osteoblastic activity at the compression site.

11. A. Abnormal mobility at fracture site

Pain is the M/C symptom and tenderness is the M/C sign of fresh fracture but the surest/diagnostic signs are abnormal mobility of bone or loss of transmitted movements. Note: crepitus is not a specific sign.

12. B. Bony tenderness

Pain is the M/C symptom and tenderness is the M/C sign of fresh fracture but the surest/diagnostic signs are abnormal mobility of bone or loss of transmitted movements. Note: crepitus is not a specific sign. Bony deformity is not always present with fracture.

13. B. Spiral fracture (because the nature of trauma is a twisting injury).

Fracture Types:

- Transverse –caused by bending force
- Oblique - caused by axial compression combined with bending and compression.
- Spiral – caused by twisting strain
- Direct trauma – transverse > comminuted fracture.

14. A. Hematoma formation

Haematoma formation is the earliest stage of fracture healing and all other options can lead to fracture non-union.

15. D. All of the above

Adequate immobilisation, vascularity and sterility (i.e abscence of infection) are pre-requisite to fracture healing.

16. C. Open segmental fractures, open fracture extensive soft tissue damage

Gustilo-Anderson classification of compound fractures*	
Type/ Grade	**Features**
I	Fracture wound < 1 cm with minimal soft tissue injury and fracture comminution. Usually it is low energy trauma with clean wound.
II	Fracture wound > 1 cm without extensive soft tissue damage and fracture comminution. There is mild-to-moderate soft tissue injury and mild-to-moderate wound contamination.
IIIA	Fracture wound > 10 cm with extensive soft tissue injury and wound contamination, but with adequate soft tissue coverage (at least periosteum over bone is intact).
IIIB	Fracture wound > 10 cm with extensive soft tissue damage and contamination. Soft tissue coverage is inadequate (periosteal stripping occurs and bone may be exposed) and require skin or flap grafting
IIIC	Any size of open wound with major vascular injury requiring repair.

17. A. Debridement

All open fractures are first managed by ATLS protocol. Than treatment specific - antibiotic → debridement

→ external fixation with or without skin coverage, as need be.

18. C. Grade 3a(Comminuted fracture)

Gun shot wounds with fractures and open segmental fractures are classified as type III Gustilo-Anderson injuries.

19. A. IIIC

Open fracture requiring vascular repair is classified as grade IIIC.

20. A. Stabilisation

In hypertrophic non – union, the body physiology is allright and there is abundant callus, and non-union is due to inadequate immobilisation. Thus treatment is only stabilisation without bone grafting.

21. A. Vascular ischemia

Compartment syndrome is a delayed complication, while malunion and AVN is late complication.

22. A. Osteoporosis

23. B. Sex

Sex / gender does not affect fracture healing, while age (Old age), loss of vascularity and comminution delays fracture healing.

24. B. Woven bone

At the stage of consolidation, Woven bone formation occurs and it restricts movements in all planes as it is hard and strong, thus also known as hard callus. Haematoma formation and callus are the initial stage of fracture healing.

25. B. Inadequate immobilization

All the above mentioned options are causes of non-union, but inadequate immobilisation is the M/C cause of fracture non-union.

26. A. Iliac crest

Illiac crest is the M/C site of bone graft and is richj in cortico-cancellous/cancellous graft. All other mentioned options are rich in cancellous bones, but less commonly used for bone graft.

27. A. Lower end radius

Lower end radius is the M/c site of epiphyseal injury in children.

28. B. Angulation in metaphysis.

Angulation remodels better than rotation and metaphysis being cancellous active vascular bone remodels best.

29. D For treating tuberculosis of knee

This is the reason, Thomas splint is aka T.K.splint.

30. C. Concave

The concave side of plaster is manipulated with a wedge, to re-reduce the fracture properly.

31. B. Osteoporosis

All the above mentioned options are causes of pathological fracture, but osteoporosis is the M/C cause of pathological fracture and question asked is generalised affection, where osteoporosis is the only relevant option.

32. A. Internal Fixation

It is always managed surgically by internal fixation and all other options are pertinent to conservative management. External skeletal fixation has no role in management of pathological fracture.

33. A. Infection

Infection is the closest D/D of stress fracture.

34. D. Stress fracture

Army recruit, acute point tenderness, aggravated on physical activity point towards stress fracture. There is no point tenderness in lumbar canal stenosis and Buerger's disease.

35. A patient of s/c # is unable to flex his inter-phalangeal joint of thumb. Which nerve is most likely injured?

A. Median nerve
B. Radial nerve
C. Ulnar nerve
D. AIN.

36. Which of the following is true about anterior shoulder dislocation?

A. It is most common type of shoulder dislocation.
B. It is most commonly subclavicular.
C. Patient keeps his arm in saluting position.
D. Injury to brachial plexus may occur.

37. Hamilton Ruler test sign is positive in which of the above mentioned conditions?

A. Anterior dislocation of shoulder.
B. Acromioclavicular joint dislocation.
C. Posterior dislocation of shoulder.
D. Luxatio erecta.

38. An adult patient reported to emergency with limited adduction/IR with the following xray, Diagnosis is?

A. Anterior dislocation of shoulder
B. Posterior dislocation of shoulder
C. Superior dislocation of shoulder
D. Inferior dislocation of shoulder

39. Nerve injured in anterior dislocation of shoulder?

A. Radial
B. Axillary
C. Long thoracic
D. Median

40. Neglected shoulder dislocation in a young labourer is?

A. Medically managed
B. Surgically managed
C. Neglected
D. Counselled

41. Which is true regarding shoulder dislocation?

A. Posterior dislocation is often over-looked
B. Pain is severe in anterior dislocation
C. Radiography may be misleading in posterior dislocation
D. All of the above

42. Which of the following is test of posterior Glenohumeral instability?

A. Fulcrum
B. Sulcus test
C. Jerk test
D. Crank test

43. Shoulder X- Ray highest bony landmark is?

A. Greater tuberosity
B. Lesser tuberosity
C. Head
D. Acromion

44. Zanca's view is done for?

A. AC joint dislocation
B. Shoulder dislocation
C. Cervical spine
D. Sterno-clavicular joint dislocation

45. Most common complication of mid shaft humerus fracture is?

A. Radial nerve palsy
B. Median nerve palsy
C. Nonunion
D. Malunion

46. Proximal humerus fracture which has maximum chances of avascular necrosis?

A. One part
B. Two part
C. Three part
D. Four part

47. Posterior Elbow dislocation most common nerve involved is?

A. Ulnar
B. Median
C. Radial
D. Musculocutaneous

48. Name of this type of immobilisation:

A. Velpaeu bandage
B. Cuff and collar sling
C. Arm pouch
D. Aeroplane splint.

35. d	36. a	37. a	38. a	39. b	40. b	41. d	42. c	43. d	44. a	45. a	46. d	47. a	48. a	

49. A child presents with the following deformity most common etiology is?

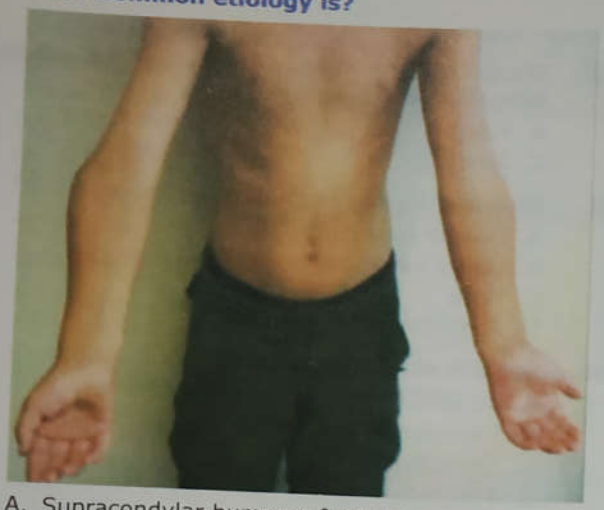

A. Supracondylar humerus fracture
B. Lateral condyle humerus fracture
C. Radial head dislocation
D. Monteggia fracture dislocation

50. Preferred treatment of cubitus varus is?

A. Medial closing wedge osteotomy
B. Lateral closing wedge osteotomy
C. Medial opening wedge osteotomy
D. Lateral opening wedge osteotomy

51. In Supracondylar fracture of humerus in children if the radial pulse is absent, what is next line of management?

A. Emergency brachial artery exploration
B. Closed reduction of fracture and look of reappearance of pulse
C. Closed reduction, above elbow slab plaster and observe
D. Open reduction and internal fixation of fracture.

52. Pointing index is a complication seen in?

A. Lateral humeral condyle fracture
B. Supracondylar fracture of humerus
C. Shoulder dislocation
D. Fracture of shaft of humerus

53. The most common type of elbow dislocation is?

A. Posterior
B. Posteromedial
C. Posterolateral
D. Lateral

54. All of the following are complications of supracondylar fracture of humerus in children, except?

A. Compartment syndrome
B. Myositis ossificans
C. Malunion
D. Non- union

55. Malunited Supracondylar fracture humerus causes:

A. Static cubitus varus
B. Progressive Cubitus varus
C. Cubitus valgus
D. Shortening

56. Late complication of elbow dislocation:

A. Median nerve injury
B. Brachial artery injury
C. Myositis ossification
D. All of the above

57. Deformity in posterior elbow dislocation:

A. Flexion
B. Extension
C. Both
D. None

58. What is seen on X-ray with posterior elbow dislocation:

A. Coronoid process posterior to humerus
B. Coronoid process anterior to humerus
C. Coronoid process below humerus
D. None

59. Supracondylar fracture humerus treatment is:

A. Open reduction and K-wire fixation
B. Closed reduction and K-wire fixation
C. Excision
D. Below elbow slab

60. A six-year-old child presented with a valgus deformity at his right elbow since 3 years that is gradually progressive. He has a history of cast applied for 6 weeks after fall on outstretched hand 3 year back. The probable fracture was?

A. Lateral Condylar fracture of Humerus
B. Supracondylar fracture of Humerus
C. Posterior dislocation of elbow
D. Fracture medial condyle of Humerus

61. Most common complication of lateral condyle humerus fracture?

A. Malunion
B. Non-union
C. VIC
D. Median nerve injury

62. Which fracture requires open reduction in children?

A. Fracture of both bones of forearm
B. Epiphyseal separation of tibia
C. Intercondylar fracture of femur
D. Lateral condyle fracture humerus

63. Tardy ulnar nerve palsy seen in?

A. Medial condyle fracture humerus
B. Lateral condylar fracture humerus
C. Supracondylar fracture humerus
D. Fracture shaft humerus

64. Which is the earliest reliable sign of compartment syndrome?

A. Stretch pain
B. Pulselessness
C. Paraesthesia
D. Pallor

49. a	50. b	51. b	52. b	53. a	54. d	55. a	56. c	57. a	58. a	59. b	60. a	61. b	62. d
63. b	64. a												

65. Use of this splint:

A. VIC
B. Radial nerve injury
C. Myositis ossificans
D. Claw hand.

66. A cause of comminuted fracture of tibia presenting with severe pain in the calf on dorsiflexion of the foot. There is also numbness on the sole of foot. Distal pulses are present. What is the probable diagnosis?

A. Rupture of Achilles tendon
B. Gastrocnemius and soleus muscle tear
C. Compartment syndrome
D. Tarsal tunnel syndrome

67. Most common cause of acute compartment syndrome in children is?

A. Fracture supracondylar humerus
B. Transphyseal humerus fracture
C. Fracture radius/ ulna
D. Fracture shaft humerus

68. Volkmann's contracture, which artery is involved?

A. Radial
B. Brachial
C. Ulnar
D. Interosseus

69. Dye is injected in one of the extremities in a child and is followed by pain and swelling of upper limb, Paresthesias of fingers, stretch pain and normal peripheral pulses, management is?

A. Aspiration
B. Anti- Inflammatory
C. Observation
D. Fasciotomy

70. All of the following are features of myositis ossificans expect?

A. Commonly occurs around the elbow
B. It matures from inside out
C. Massage is a known associated factor
D. Can be post- traumatic

71. Most common site of myositis ossificans?

A. Knee
B. Elbow
C. Shoulder
D. Wrist

72. False about myositis ossificans progressiva (child with heterotopic ossifications) is?

A. Pneumonia is common
B. Life longevity is common
C. Most common site involved is the spine
D. Onset is before 6 year

73. A person of 60 year age is suffering from myositis ossificans progressive. The usual cause of death?

A. Nutritional deficiency
B. Bed sore
C. Lung disease
D. Septicemia

74. Treatment of Acute Myositis Ossificans is?

A. Active mobilization
B. Passive mobilization
C. Infra Red Therapy
D. Immobilization

75. What is not true about pulled elbow?

A. Occurs due to sudden axial pull on extended elbow
B. Forearm is held in pronation and extention
C. Most commonly occurs between 2-5 year of age
D. Treatment is quick pronation and flexion of elbow

76. Name the type of surgery done in this case :

A. Radial head replacement
B. ORIF for radial head
C. Total elbow replacement
D. Fixation for radial neck

77. Essex lopresti lesion in upper limb?

A. Injury to interosseous membrane
B. Radial head fracture
C. Radial shaft fracture
D. Radial shaft and radio- ulnar joint fracture

78. Excision of head of radius in a child should not be done because?

A. It produces instability of elbow joint
B. It leads to secondary Osteoarthritis of elbow
C. It causes subluxation of inferior radio-ulnar joint
D. It causes myositis ossificans

65. a	66. c	67. a	68. b	69. d	70. b	71. b	72. b	73. c	74. d	75. d	76. a	77. a	78. c

79. In fracture of the olecranon, excision of the proximal fragment is indicated in all of the following situation except?

A. Old ununited fractures
B. Non- articular fractures
C. Fracture extending to coronoid process
D. Elderly patient

80. What is the diagnosis of this fracture?

A. Monteggia fracture type
B. Side swipe fracture
C. Galeazzi fracture
D. Monteggia fracture type

81. Name of the fracture for which this surgery is done:

A. Galleazi fracture
B. Monteggia fracture
C. Wrist subluxation
D. Fracture radius

82. Posterior interosseous nerve is injured in?

A. Posterior dislocation of elbow
B. Monteggia fracture dislocation
C. Reversed Monteggia fracture dislocation
D. Supracondylar fracture of humerus

83. AP & Lat. View of wrist is given. What is your diagnosis?

A. Galleazzi
B. Monteggia
C. Smith
D. Colles

84. Fracture of proximal BBFA, cast position is?

A. Pronated flexion
B. Neutral position
C. Supinated position
D. Position does not matter

85. The treatment of choice of fracture of radius and ulna in an adult is?

A. Plaster for 4 weeks
B. Closed reduction and calipers
C. Reduction and stabilization with plating
D. Kuntscher nails

86. Which of the following is true about Colles fracture?

A. Volar angulation with Radius deviation occurs
B. It is an intra articular fracture
C. It may lead to gunstock deformity due to Malunion
D. It is associated with dorsal angulation.

87. Commonest fracture in elderly with fall on outstretched hand is?

A. Colles fracture
B. Bennetts fracture
C. Galeazzi fracture
D. Monteggia fracture

88. Most common complication of Colles?

A. Malunion
B. Avascular necrosis
C. Finger stiffness
D. Rupture of EPL tendon

89. A lady with Colles fracture. The fracture healed but after few days patient develops pain and swelling over wrist and forearm, red hot and shiny skin and on X- Ray patchy osteopenia is seen. Diagnosis is?

A. Sudeck's osteodystrophy
B. Causalgia
C. Non- union
D. Nerve injury

90. Sudeck's dystrophy symptoms are all except?

A. Pain
B. Increased bone density
C. Sweating
D. Stiffness

91. Stellate ganglion block is useful in?

A. Sudeck's osteodystrophy
B. Compound palmar ganglion
C. Tenosynovitis
D. Osteoarthritis of first CMC joint

92. Management of Smith's fracture is?

A. Open reduction and fixation
B. Plaster cast with forearm in pronation
C. Closed reduction with below-elbow cast
D. Above- elbow cast with forearm in supination

79. c	80. a	81. a	82. b	83. a	84. c	85. c	86. d	87. a	88. c	89. a	90. b	91. a	92. d

93. Barton's fracture of the wrist?

A. Involved radiocarpal subluxation
B. Is a severe from of Colles' fracture
C. Is often treated by cast
D. All of the above

94. Which one of the following statements is not correct regarding fracture of the scaphoid?

A. It is the most commonly fractured carpal bone
B. Persistent tenderness un the anatomical snuffbox is highly suggestive of fracture
C. Immediate X- ray of hand may not revel fracture line
D. Malunion is a frequent complication

95. In children fracture scaphoid is though rare but usually involves?

A. Waist
B. Proximal pole
C. Neck
D. Distal pole

96. In non- union of scaphoid vascularized muscle pedicle graft is taken form?

A. Pronator teres
B. Brachioradialis
C. Pronator quadratus
D. Extenson pollicis longus

97. One of the common fracture that occur during boxing by hitting with a closed first is?

A. Monteggia fracture dislocation
B. Galeazzi fracture dislocation
C. Bennett's fracture dislocation
D. Smith's fracture

98. Boxer's fracture is?

A. Radial styloid fracture
B. Reverse colle's fracture
C. 5th metacarpal fracture
D. 1st metacarpal fracture

99. Rolando fracture involves base of?

A. 1st metacarpal
B. 2nd metacarpal
C. 3rd metacarpal
D. 4th metacarpal

100. A Bennett's fracture is difficult to maintain in a reduced position mainly because of the pull of the?

A. Flexor pollicis longus
B. Flexor pollicis brevis
C. Extensor pollicis longus
D. Abductor pollicis

93. a	94. d	95. d	96. c	97. c	98. c	99. a	100. d

35. D. AIN

Flexow pollicis longus is supplied by AIN. M/C nerve injury I # S/C humerus is AIN.

36. A. It is most common type of shoulder dislocation

It is the M/C dislocation, M/C type being subcoracoid.

37. A. Anterior dislocation of shoulder

Hamilton ruler, Dugas, callaway tests are positive in anterior dislocation of shoulder.

38. A. Anterior dislocation of shoulder

Limited adduction & IR with this xray – s/o anterior dislocation shoulder.

39. B. Axillary

Axillary nerve is at risk in anterior dislocation of shoulder.

40. B. Surgically managed

Neglected shoulder dislocation in a young labourer (i.e high demand patient) is managed surgically, as it is very difficult to reduce the shoulder by traction alone.

41. D. All of the above.

Posterior dislocation is often overlooked, thus it is aka missed injury. It is also very difficult to diagnose the same on Xray.

42. C. Jerk test

Fulcrum, Crank – anterior instability, Sulcus – inferior instability.

43. D. Acromion

- See the normal xray of shoulder joint to know the bony landmarks.

44. A. AC joint dislocation.

AC joint – zanca's view, Shoulder dislocation – scapular y view.

45. A. Radial nerve palsy

Radial nerve is M/C injured in fracture shaft humerus.

46. D. Four part.

As the number of parts increases, chances of AVN also increase. 4 part fracture has maximum chances of AVN.

47. A Ulnar

Ulnar is the M/C nerve injured, given its anatomical location.

48. A. velpaeu bandage

It was used earlier for immobilisation of shoulder joint.

49. A. Supracondylar humerus fracture

S/C fracture humerus – Cubitus varus, # non-union lateral condyle fracture – cubitus valgus.

50. B. Lateral closing wedge osteotomy

Lateral closed wedge osteotomy is preferred over medial open wedge, due to problem of taking bone graft and traction neuritis,etc.

51. B. Closed reduction of fracture and look of reappearance of pulse

Closed reduction and flex the elbow till the pulse reappears, and than immobilise the ebow in that position.

52. B. Supracondylar fracture of humerus

- M/C nerve injury is AIN>Median>radial (these three in extension type) > ulnar (in flexion type & post surgery). AIN / median nerve injury will lead to pointing index sign.

53. A. Posterior

Posterior > posterolateral.

54. D. Non- union

Supracondylar fracture maunites and lateral condyle fracture goes into non-union, if unmanaged.

55. A. Static cubitus varus

Cubitus varus due to malunited S/C fracture is a static deformity, whereas cubitus valgus due to lateral condyle non-union is a progressive deformity.

56. C. Myositis ossification

Nerve / artery injury is an immediate complication, whereas Myositis ossificans is a late complication.

57. A. Flexion

Olecranon is prominent posteriorly in posterior elbow dislocation, leading to flexion deformity in elbow.

58. A. Coronoid process posterior to humerus.

Olecranon is dislocated posteriorly leading to coronoid being posterior to humerus.

59. B. Closed reduction and K- wire fixation

Ideal treatment is closed reduction and K wire fixation, with an above elbow POP slab. If fracture cannot be reduced closed, than open surgery may be required in type III or type IV case.

60. A. Lateral Condylar fracture of Humerus

This is a case of fracture lateral condyle humerus which was managed conservatively, leading to non-union and thus a valgus deformity at elbow.

61. B. Non-union

Supracondylar fracture maunites and lateral condyle fracture goes into non-union, if unmanaged.

62. D. Lateral condyle fracture humerus

Lateral condyle fracture is aka fracture of necessity, as it is always managed surgically (Open reduction and fixation with K wire).

63. B. Lateral condylar fracture humerus
C. Supracondylar fracture humerus.

Tardy ulnar nerve palsy is seen in valgus deformity due to traction in ulnar nerve. Rarely Malunited fracture S/C humerus ma also lead to tardy ulnar nerve palsy.

64. A. Stretch pain

Stretch pain is the earliest reliable sign and pulse is the least reliable sign.

65. A. VIC.

Turn buckle splint used in VIC.

66. C. Compartment syndrome

It is case of compartment syndrome of leg, specifically posterior compartment.

67. A. Fracture supracondylar humerus

Fracture radius / ulna are also known to cause compartment syndrome in children, but # S/C humerus is the M/C cause in children.

68. B. Brachial

Brachial artery and Anterior interosseous nerve is involved.

69. D. Fasciotomy

This is case of compartment syndrome, and is managed by fasciotomy. In cases of impending compartment, observation has a role, but not in established compartment.

70. B. It matures from inside out

It matures outside – in, the most important differentiating feature with osteosarcoma.

71. B. Elbow

Elbow is the M/C site of myositis ossificans.

72. B. Life longevity is common

Life longevity is decreased due to cardio-pulmonary issues.

73. C. Lung disease

The M/C cause of death is lung disease.

74. D. immobilization

Immobilisation / rest is the most important treatment in acute period.

75. D. Treatment is quick pronation and flexion of elbow

Treatment is quick supination and flexion of elbow.

76. A. Radial head replacement

Radial head is replaced with an artificial prosthesis (as is done in hip replacement).

77. A Injury to interosseous membrane

Essex Lopresti lesion is radial head fracture with interosseous membrane injury with inferior RU joint dislocation. Central to this, is the interosseous membrane injury.

78. C. It causes subluxation of inferior radio-ulnar joint

Excision is always contraindicatio in children because of growth disturbance between radius and ulna, proximal migration of radius leading to inferior RU joint subluxation > elbow instability and cubitus valgus deformity

79. C. Fracture extending to coronoid process

Excision is C/I where it may lead to elbow instability, eg. fracture extending distally to coronoid

80. A Monteggia fracture type

Ulna fracture with superior radio-ulnar dislocation – Monteggia fracture.

81. A. Galleazi fracture.

I the given Xray – plating in radius is done (# radius) with K wire across distal radio-ulnar joint (DRUJ dislocation), thus the diagnosis is Galleazi fracture.

82. B. Monteggia fracture dislocation

In Monteggia fracture, most commonly nerve injury is that of PIN. Most commonly injured in type II/III.

83. A. Galleazzi

Fracture radius with DRUJ dislocation – galleazi fracture.

84. C. Supinated position

Proximal BBFA – Supination, Distal BBFA – pronation, Mid BBFA – neutral position.

85. C. Reduction and stabilization with plating

Adult BBFA fracture is always managed surgically with plating.

86. D. It is associated with dorsal angulation

Volar angulation – smith fracture, Intra-articular fracture – Barton fracture, gunstock deformity- C. Varus due to malunited # S/C humerus.

87. A. Colles fracture

Colles fracture is the M/C fracture in elderly.

88. C. Finger stiffness

Joint/finger stiffness > malunion (not non-union).

89. A. Sudeck's osteodystrophy

Clinical picture is characteristic of Sudeck's osteodystrophy.

90. B. Increased bone density

There is osteopenia due to increased blood flow, not increased bone density.

91. A. Sudeck's osteodystrophy

Stellate ganglion block is useful in Sudeck's osteodystrophy for pain management and also the disease process, as it is believed that, the disease is due to sympathetic overactivity.

92. D. Above- elbow cast with forearm in supination

Treated in **above elbow** cast in dorsal angulation, lateral deviation in supination.

93. A. Involved radiocarpal subluxation

This is an intra-articular fracture of DER in which carpus and a rim of distal radius are displaced together, thus it is fracture dislocation.

94. D. Malunion is a frequent complication

M/C complication : Non union (Hump back deformity) > AVN. Malunion is rarely seen.

95. D. Distal pole

Waist fracture is common in adults, but in children distal pole is M/C fractured.

96. C. Pronator quadrates

In cases of non-union, vascularised muscle pedicle graft can be done, taken most common from pronator quadrates

97. C. Bennett's fracture dislocation

Bennets fracture is common in boxers while hitting with a closed fist, but the fracture M/C in boxers is Boxers fracture.

98. C. 5th metacarpal fracture

Fracture neck of 5th metacarpal is Boxers fracture.

99. A. 1st metacarpal

Rolando fracture – V or Y or T shaped intra-articular fracture of base of 1st metacarpal.

100. D. Abductor pollicis

Distal fragment is pulled laterally and proximally by unopposed pull of abductor pollicis longus

101. Name of the injury for which this surgery is done

A. Fracture I/T femur
B. Fracture S/T femur
C. Fracture SOF
D. Fracture head of femur

102. What is a floating knee?

A. Damage to both anterior and posterior cruciate ligament
B. Condition of knee due to tear in medial and lateral collateral ligaments
C. Femoral shaft fracture with proximal tibia metaphyseal fracture
D. Advanced tuberculosis of knee joint

103. Exsanguinating blood loss in

A. Closed humerus fracture
B. Closed tibia fracture
C. Open femur fracture
D. Open humerus fracture

104. The Femur is Fracture at birth at

A. Upper third of shaft
B. Middle third of Shaft
C. Lower third of shaft
D. Neck region

105. Name the type of traction:

A. Gallows traction
B. Bryant's traction
C. Perkin's traction
D. Dunlop traction

106. Thomas splint most troubling is

A. Ring
B. Side bars
C. Gauze support
D. Traction attachment

107. Regarding Guard's criteria all correct except:

A. Pulmonary edema is major criterion
B. Thrombocytopenia is a major criteria
C. 1 major + 4 major criteria required to diagnose as fat embolism
D. $PaO_2 < 60$ is a major Criteria

108. A person with multiple injuries develops fever restlessness, tachycardia, tachypnea and subconjuctival rash after 48 hours of injury. The likely diagnosis is

A. Air embolism
B. Fat embolism
C. Pulmonary embolism
D. Bacterial pneumonitis

109. What is method of fixation of this fracture?

A. Plating
B. Nailing
C. Screws
D. Tension band Wiring

110. Install-Salvati index is used for

A. Olecranon
B. Patella
C. Talus
D. Scaphoid

111. Mechanism of injury in lateral condylar fracture of proximal tibia

A. Strain of valgus knee
B. Strain of varus knee
C. Strain of valgus knee with axial loading
D. Rotational injury

112. Patellar tendon bearing cast is indicated in the following fracture:

A. Patella
B. Tibia
C. Medial malleolus
D. Femur

101. a	102. c	103. c	104. a	105. a	106. a	107. b	108. b	109. d	110. b	111. c	112. b

113. Name of this cast is:

A. PTB cast
B. Below knee cast
C. Above knee cast
D. Cylindrical cast

114. Ottawa ankle rules are used to

A. Diagnose rupture of Achilles tendon
B. Decide on treatment for CTEV
C. Decide on need of X-ray for possible fracture
D. Decide on immediate vs. delayed treatment of ankle dislocation

115. Diagnosis of the xray:

A. Pilon fracture
B. Aviators fracture
C. Pott's fracture
D. Lovers fracture

116. March fracture involves

A. 1st and 2nd metatarsal
B. 2nd and 3rd metatarsal
C. 3rd and 4th metatarsal
D. 4th and 4th metatarsal

117. Fracture involving both the malleoli is

A. Cotton's fracture
B. Pott's fracture
C. Pirogoff's fracture
D. Dupuytren's Fracture

118. Avascular necrosis is a complication of

A. Fracture of talus
B. Fracture of medial condyle of femur
C. Olecranon fracture
D. Radial head fracture

119. One of the following fracture required plaster of Paris cast with equines position

A. Distal Fracture both bones leg
B. Distal fracture fibula
C. Bimalleolar
D. Fracture Talus

120. Bohler's angle is for

A. Talus
B. CTEV
C. Calcaneum
D. Scaphoid

121. Gissane'sangle in intra-articular fracture of Calcaneum:

A. Reduced
B. Increased
C. Not Changed
D. Variable

122. Calcaneum is associated most commonly with which

A. Fracture rib
B. Fracture vertebrae
C. Fracture skullD.
Fracture fibula

123. Least common complication of fall from height is

A. Fracture base of skull
B. Fracture calcaneum
C. Fracture fibula
D. Fracture 12th thoracic vertebra

124. Watson – Jones procedure is done for

A. Polio
B. Muscle paralysis
C. Neglected clubfoot
D. Chronic ankle instability

125. Diagnosis of the given xray

A. Lisfranc fracture
B. Fracture base of 2nd MT
C. Fracture of cuneiform
D. Metatarsal fracture

113. a	114. c	115. a	116. b	117. b	118. a	119. d	120. c	121. b	122. b	123. c
124. d	125. a									

126. Jone's fracture is

A. Fracture of base of 5th metatarsal
B. Fracture of base of 2nd metatarsal
C. Fracture of base of 1st metacarpal
D. Fracture of head of 5th metacarpal

127. Chauffeur's fracture involves the

A. Radial head
B. Radial styloid
C. Ulnar styloid
D. Base of 1st metacarpal

128. Tillaux fracture involves

A. Lower end tibia
B. Upper end tibia
C. Lower end femur
D. Upper end femur

129. Bosworth fracture

A. Fracture distal fibula with posterior dislocation of proximal fragment
B. Fracture distal fibula with dislocation of distal fragment
C. Fracture distal end tibia
D. Fracture distal end femur

130. Pellegrini-stieda Disease is

A. Avulsion of femoral attachment of MCL
B. Avulsion of tibia attachment of MCL
C. Avulsion of femoral attachment of LCL
D. Avulsion of tibial attachment of LCL

131. Toddler fracture involves

A. Femur
B. Tibia
C. Fibula
D. Talus

126. a	127. b	128. a	129. a	130. a	131. b

101. A. fracture I/T femur

The Implant shown is Dynamic hip screw (DHS), used in I/T femur fracture and also Basicervical NOF fracture. In # S/T femur PFN and # SOF ILN is used respectively.

102. C. Femoral shaft fracture with proximal tibiametaphyseal fracture

When both tibia an femur are fractured, the knee floats freely and is k/a floating knee.

103. C. Open Femur Fracture

Pelvis > femur fracture leads to maximum amount of blood loss.

104. A. Upper third of shaft

At birth / in children, Fracture SOF is M/C at upper third region.

105. A Gallow's traction

Image shown is of Gallow's traction used for # SOF in child <2years age. Bryant's traction is combination of (gallows & Bucks traction). Perkins traction is a skeletal traction, & Dunlop traction is used for # S/C humerus.

106. A. Ring.

Because it impinges against proximal thigh

107. B. Thrombocytopenia is a major criteria

Thrombocytopenia is a minor criteria. 1 major + 4 minor or 2major criteria is required to make a diagnosis.

Guard's criteria for fat embolism

Major criteria	Minor criteria
Axillary or subconjuctival petichiae	Tachycardia >110
Hypoxemia PaO2 <60mmhg	Pyrexia >38•5
CNS depression disproportionate to hypoxemia	Retinal embolism on fundoscopy
	Fat globules on urine and sputum
	Increase in ESR, decreased hematocrit or platelets

108. B. Fat embolism

After multiple injuries / polytrauma, fat embolism usually develops after 48 hours with the above mentioned clinical signs and symptoms.

109. D. Tension band wiring

Xray is suggestive of simple displaced fracture patella, managed M/C by TBW. Plating and screws can also be used in some cases.

110. B. Patella

Install-Salvati index is considered normal b/w. 8-1.2, and ratio <.8 is k/a patella baja and >1.2 is k/a patella alta.

111. C. Strain of valgus knee with axial loading.

Strain on a valgus knee with axial loading l/t # lateral condyle & strain on a varus knee l/t medial condyle fracture of proximal tibia.

112. B. Tibia

It is a misnomer and is used for # tibia not patella.

113. A. PTB cast

The cast bears the patellar tendon and thus the name, used for fracture tibia. Cylindrical cast extends from mid thigh to ankle region, used for fracture patella.

114. C. Decide on need of X-ray for possible fracture

Ottawa ankle rule is used for assessing ankle injury patients and Xrays are prescribed, i.e fracture of malleoli is suspected, when patient's clinical features fulfils Ottawa ankle rule.

115. A. pilon fracture

Pilon fracture is the intra-articular fracture of distal tibia. Aviators fracture involves talus, Pott's fracture is the term used for bimalleoli fracture and lovers fracture for # calcaneum.

116. B. 2nd and 3rd metatarsal

Fracture of 2nd > 3rd metatarsal shaft is k/a March fracture, a type of stress fracture.

117. B. Pott's Fracture

Cottons fracture – trimalleoli fracture, Dupuytren's's fracture – a variety of bimalleolar fracture where the re is fracture of distal fibula with tibio-fibular and deltoid ligament tear with +/- medial malleolus fracture.

118. A. Fracture of talus

AVN is a complication of – Fracture waist of scaphoid, neck of femur fracture and fracture neck talus, due to its vulnerable blood supply.

119. D. Fracture talus

Fracture talus gets reduced in plantar flexion / equinus position and cast / slab is applied in that position.

120. C. Calcaneum

Kite's angle: CTEV

Bohler and Gissane'a angles: Calcaneum fractures

Neutral triangle: Calcaneum

121. B Increased

Xray signs on lateral view (helpful in deciding treatment)

- Bohler's angle: A decrease in Bohler's angle indicates collapse of the weight bearing posterior facet.
- Gissane's Angle: An increase in this angle represents the collapse of posterior facet.
- Neutral triangle of calcaneum: The triangle is distorted in calcaneal fractures.

122. B Fracture Vertebrae

M/C mechanism of calcaneal fracture is fall from height, thus M/C fracture associated is vertebral fracture.

123. C. Fracture fibula.

Fractures seen in fall from height – calcaneal fracture, pelvic fracture, vertebral fracture, esp. the junctional area and fracture base of skull.

124. D. Chronic ankle instability

Watson Jones surgical approach is an antero-lateral approach to hip and Watson Jones surgical procedure is done for chronic ankle instability.

125. A. Lisfranc fracture

Xray shows fleck sign. i.e increased space b/w 1st & 2nd metatarsal with chip fracture of 2nd MT base, where Lisfranc ligament is attached, diagnostic of Lisfranc fracture.

126. A. fracture of base of 5th metatarsal.

Avulsion fracture due to peroneus brevis tendon is pseudo-Jones fracture and fracture base of 5th MT base is Jones fracture.

127. B Radial styloid.

Fracture of radial styloid is k/a Chauffers fracture.

128. A. Lower end tibia

Tillaux fracture: This is avulsion of anterior tibial margin by the anterior tibiofibular ligament (Salter Harris type III injury)

129. A. Fracture distal fibula with posterior dislocation of proximal fragment

- Bosworth fracture – fracture of distal fibula with posterior displacement/entrapment of proximal fragment behind tibia.

130. A. Avulsion of femoral attachment of MCL

Injury at the femoral attachment of MCL with new bone formation.

131. B. Tibia

Toddler fracture- seen in children <3yrs old, minimally displaced spiral/oblique fracture of tibia without fracture of fibula and is also known as CAST (Childhood accidental spiral tibial) fracture.

132. True about articular cartilage

A. Is a type of elastic cartilage
B. Is hyaline cartilage on the articular surface of bones
C. Is type 1 cartilage providing compressive strength
D. Is hyaline cartilage found in growth plate of bones

133. Joint erosion is not a feature in

A. SLE
B. Gout
C. Psoriasis
D. Rheumatoid arthritis

134. The father of joint replacement surgery is:

A. Manning
B. Girdlestone
C. Charnley
D. Ponsetti

135. All of the following statements about synovial fluid are true, except

A. Secreted primarily by type a synovial cells
B. Follows Non-Newtonian fluid kinetics
C. Contains hyaluronic acid
D. Viscosity is variable

136. Following X-ray changes are seen in

A. OA
B. RA
C. Psoriasis
D. Pseudogout

137. Pain and arthritis of distal interphalangeal joints seen in:

A. Osteoarthritis
B. Rheumatoid arthritis
C. Ankylosing spondylitis
D. Dequervain's disease

138. Arthritis involving DIP, PIP, 1st carpometacarpal with sparing of MCP and wrist joint is typical of

A. Osteoarthritis
B. Rheumatoid arthritis
C. Ankylosing spondylitis
D. Psoriatic arthritis

139. Which can cause loose body in the joint:

A. RA
B. Ankylosing spondylitis
C. OA
D. SLE

140. In patient with osteoarthritis of knee joint, atrophy occurs most commonly in which muscle

A. Quadriceps only
B. Hamstrings only
C. Both A and B
D. Gastrocnemius

141. Severe disability in primary osteoarthritis of hip is best managed by

A. Arthrodesis
B. Arthroplasty
C. McMurray's hydrocortisone and physiotherapy
D. Intra- articular hydrocortisone and physiotherapy

142. True about Boutonniere deformity is/are

A. Rupture of extensor tendon
B. Initially joints are mobile followed by rigidity
C. Flexion at PIP joint and extension at DIP
D. All of the above

143. Rheumatoid arthritis affects which region of the spinal column?

A. Cervical spine
B. Thoracic spine
C. Lumbosacral spine
D. Equally affects all regions

144. Windswept deformity of the knee is seen in:

A. Osteoarthritis
B. Rheumatoid arthritis
C. Ankylosing Sponylitis
D. Psoriatic arthritis

145. Abatacept is used for

A. Rheumatoid arthritis
B. Ankylosing Sponylitis
C. Osteoarthritis
D. SLE

146. Earliest radiological change in RA:

A. Decreased joint space
B. Articular erosion
C. Periarticular osteopenia
D. Subchondral cyst

132. b	133. a	134. c	135. a	136. a	137. a	138. a	139. c	140. a	141. b	142. d
143. a	144. b	145. a	146. c							

147. Which arthritis causes no periosteal reaction:

A. Psoriatic arthritis
B. Reactive arthritis
C. Neruropathic arthritis
D. Rheumatoid arthritis

148. All are feature of seronegative Spondyloarthropathies except:

A. Uveitis
B. RA factor positive
C. HLA-B27 positive
D. Occur in young age

149. What is pathognomic feature of rheumatoid arthritis?

A. Rheumatoid factor
B. Rheumatoid nodule
C. Morning stiffness
D. Ulnar drift of fingers

150. Which of the following is true regarding rheumatoid arthritis:

A. Typically involves small and large joints symmetrically but spares the cervical spine
B. Causes pleural effusion with low sugar
C. Pulmonary nodules are absent
D. Enthesopathy prominent

151. HLA B27 is not seen in:

A. SLE
B. Ankylosis spondylitis
C. Reiter's syndrome
D. Psoriatic arthritis

152. Young male having pain with daily morning stiffness of spine for 30 minutes and reduced chest movements. Most probable diagnosis is:

A. Ankylosis spondylitis
B. Rheumatoid arthritis
C. Gouty arthritis
D. Osteoarthritis

153. Correct statement regarding AS

A. Sacroiliitis is the earliest manifestation seen
B. Gaenslen test done
C. Peripheral joint involvement in 30% patients
D. All of the above

154. True regarding Ankylosing Spondylitis is:

A. Osteophytes grow in vertical directions
B. Most common extra articular manifestation is acute anterior uveitis
C. HLA B27 is positive in more than 90% of cases
D. All of the above

155. A young man complaints of pain lower back his X-rays are shown below. Mostlikely diagnosis is

A. AS
B. Spondylolisthesis
C. Paget's disease
D. Osteoporosis

156. Identify the test performed :

A. FABER test
B. Thomas test
C. SLR test
D. Gaenslen test

157. Ankylosing spondylitis all is true except:

A. HLA B27 is found 90% of sufferers
B. Uveitis is found in 40% of Sufferers
C. Condition is commoner in females
D. Radiological changes do not can occur in spine before symptoms

158. Differential diagnosis of hand arthritis are all excepts?

A. Ankylosis spondylitis
B. Rheumatoid arthritis
C. Psoriasis
D. Osteoarthritis

159. Bechterew's Disease?

A. R.A
B. AS
C. Paget's
D. Osteoporosis

160. CASPAR criteria is used in diagnosis of:

A. Psoriatic arthritis
B. Rheumatoid arthritis
C. Ankyosing spondylitis
D. Reactive synovitis

161. Sausage digits is seen in:

A. Lyme arthritis
B. Osteoarthritis
C. Psoriatic arthritis
D. None

162. In Psoriatic arthropathy, treatment of choice is:

A. Methotrexate
B. PUVA therapy
C. Corticosteroids
D. Indomethacin

147. d	148. b	149. b	150. b	151. a	152. a	153. d	154. a	155. a	156. a	157. c
158. a	159. b	160. a	161. a	162. a						

163. 50 yr alcoholic male with complaints of recurrent pain & swelling in foot joints. On Examination red, shiny swollen joints seen which is the most appropriate investigation to be first done considering the X-ray showing

A. HLA-B27
B. PTH levels
C. Uric acid levels
D. Calcium levels

164. Drug of choice for the treatment of acute gout in patients in whom NSAIDs are contraindicated is:

A. Colchicine
B. Allopurinol
C. Xyloric acid
D. Paracetamol

165. This elderly male came with a history of recurrent attack of pain and swelling in the great toe in the past. This is the present X-ray of the hand. The diagnosis can be confirmed by:

A. X-ray of lumbosacral spine
B. Polarized microscopy of tissue fluid aspirated
C. Anti CCP antibodies
D. HLA B27

166. Which of the following is not affected in gout?

A. Muscle
B. Skin
C. Cartilage
D. Tendon

167. What is not true about gout?

A. Abrupt increase in serum urate levels is more common a cause for acute gout than an abrupt fall in urate levels.
B. Patient may be asymptomatic with high serum uric acid for years
C. Development of arthritis correlates with level of serum uric acid
D. Uric acid arystals are best seen by polarizing light microscope

168. Periarticular calcification is seen in:

A. RA
B. Pseudogout
C. OA
D. None of the above

169. What change will be seen in vertebral column in ochronosis:

A. Calcification of disc
B. Bamboo spine
C. Increased disc space
D. None

170. How to differentiate gout with pseudogout:

A. Large joint involvement
B. Birefringent (Particles) crystals
C. Associated with Hyperparathyroidism
D. All of the above

171. Arthroscopy is contraindicated in:

A. Chronic joint disease
B. Loose bodies
C. Hemophilia
D. Meniscal tear

172. Multiple loose bodies are seen maximum in:

A. Osteochondritis dissecans
B. Synovial chondromatosis
C. Osteoarthritis
D. Rheumatoid arthritis

173. Tom smith arthritis most commonly affects?

A. Capital epiphysis of femur
B. Acetabulum
C. Neck of femur
D. Greater trochanter

174. What is the action of muscle on MCP joint as show in image?

A. Flexion
B. Extension
C. Adduction
D. Abduction

163. c	164. a	165. a	166. a	167. a	168. b	169. a	170. d	171. c	172. b	173. a
174. a										

132. B. is hyaline cartilage on the articular surface of bones

Articular cartilage is a type of hyaline cartilage.

133. A. SLE

SLE is a non-erosive arthritis.

134. C. Charnely

Sir John Charnley is considered as the "father of joint replacement surgery".

135. A. Secreted primarily by type A synovial cells

The synovial cells are of two types: Type A is primarily involved in phagocytosis while Type B secrete hyaluronic acid, proteins and prostaglandins present in synovial fluid.

136. A. OA

Osteophytes, with decreased joint space and sclerosis is diagnostic of osteoarthritis.

137. A. Osteoarthritis

DIP joint is involved in OA and characteristically spared in RA.

138. A. Osteoarthritis

OA – DIP, PIP, 1st carpo-MC joint & sparing MCP and wrist joint.

RA – MCP, PIP, wrist, sparing DIP

Psoriatic – MCP, PIP, DIP.

139. C. OA

The commonest cause of loose body in knee joint is Osteochondritis dissecans of knee. However m/c cause in elderly is OA knee. And the commonest cause of multiple loose bodies in the knee joint is Synovial chondromatosis.

140. A. Quadriceps only

Quadriceps muscle atrophies in OA, and more spec. Vastus medialis.

141. B. Arthroplasty

Arthrodesis can also alleviate pain, but restricts hip movements. In present day, hip OA is best and M/C managed by arthroplasty.

142. D. all of the above

Boutonniere deformity : Flexion contracture of PIP joints and extension of DIP joint. It is due to rupture of the central extensor expansion of the fingers.

143. A. Cervical spine

RA is a disease of synovial joint. It involves only the C1-C2 vertebrae and facet joints in the spinal column.

144. B. Rheumatoid arthritis

Genu valgum is more commonly seen in rheumatoid knees(Genu varum in OA)

Windswept deformity : Genu varum at one knee and valgum at the other, seen in RA.

145. A. Rheumatoid arthritis

It is a type of biological rug used in treatment of RA.

146. C. Periarticular osteopenia

Soft tissue swelling (earliest radiological feature) & Juxta-articular osteopenia (an early feature)

147. D. Rheumatoid arthritis

RA is not known to cause periosteal reaction.

148. B. RA factor positive

Seronegative arthritis refers to RA factor negative.

149. B. Rheumatoid nodule

RA factor is not pathognomic to RA and neither its presence is diagnostic of RA. Rheumatoid nodule is pathognomic of RA.

150. B. Causes pleural effusion with low sugar

It involves cervical spine C1-C2, and pulmonary nodules may be present in few cases. It causes Pleural and pericardial effusions (with a very low glucose content).

151. A. SLE

HLA B27- (RAPE) – RA, Ankylosing spondylitis, psoriatic, enteropathic/reactive.

152. A. Ankylosis spondylitis

Young male, spine pain, morning stiffness, decreased chest movement – diagnosis is clearly Ankylosing spondylitis.

153. D. All of the above

All the mentioned options are true for AS.

154. A. All of the above

Osteophytes grow in vertical direction causing bamboo spine appearance, iridocyclitis (anterior uveitis) is the M/c extra spinal manifestation. HLA B27 is associated in >90% cases.

155. A. AS

Bamboo spine appearance on xray in a young male with spinal pain is nothing but AS.

156. A. FABER test.

Test shown is used for AS, and is done with hip **F**lexion, **AB**duction & **EX**ternal rotation aka **FABER**.

157. C. Condition is commoner in females

AS is rare in females.

158. A. Ankylosis spondylitis

AS are not known to involve hand bones. All other three options are common in hand bones.

159. B. AS.

Ankylosing Spondylitis aka Marie Strumpell Disease/ Bechtrew's Disease.

160. A. Psoriatic arthritis

CASPAR criteria and Wright & Moll criteria are the two criterias used for diagnosis of psoriatic arthritis.

161. C. Psoriatic arthritis

Dactylitis, or "sausage digit," is a characteristic feature of the spondyloarthropathies and it is seen in up to 50% patients with psoriatic art

162. A. Methotrexate

- Antipsoriatic medicines forms the mainstay of treatment.
- MTx is the DOC.

163. C. Uric acid levels

It is a case of acute gout, and 1st investigation to be done is serum uric acid level.

164. A. Colchicine

Colchicine is very effective in pain control in gout and is the DOC in gout when NSAIDs are C/I.

165. B. Polarized microscopy of tissue fluid aspirated

It is a case of chronic gout and the investigation to confirm the same is polarized microscopy of tissue fluid aspirate. HLA B27 / xray LS spine are used for Ankylosing Spondilitid, Anti CCp for RA.

166. A. Muscle

Muscle is always spared in gouty pathology.

167. A. Abrupt increase in serum urate levels is more common a cause for acute gout than an abrupt fall in urate levels.

Fluctuation in the most important reason for acute attack of gout, decrease in urate level >> increase.

168. B. Pseudogout

Periarticular calcification is caused by CPPD deposition i.e pseudogout.

169. A. Calcification of disc

IVD are calcified in onchronosis. Bamboo spine is a feature of ankylosing spondylitis.

170. D. All of the above

Pseudogout: This is acute synovitis due to CPPD crystals, typically affecting middle-aged women. Larger joints like knee (most common site)are commonly involved. Pain is lesser compared to gout. Confirmation comes with the demonstration of positively birefringent, rhomboid-shaped crystals in the synovial fluid on joint aspiration.

171. C. Hemophilia

Arthroscopy is C/I in haemophilia due to risk of haemarthrosis.

172. B. Synovial chondromatosis

M/C cause of loose body – osteochondritis dessicans, M/C cause in elderly – OA, M/c cause of multiple loose bodies in joint – Synovial chondromatosis.

173 A. Capital epiphysis of femur

174. A. flexion

Function of lumbricals is to flex MCP joint and extend Inter-phalengeal joints.

175. Name the test done:

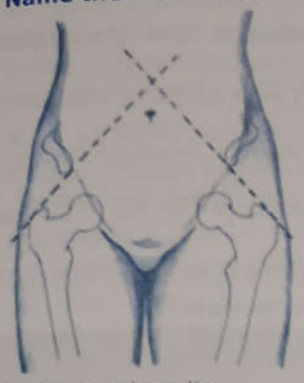

A. Shoemakers line
B. Nelatons line
C. Galleazi test
D. Thomas test

176. Trendelenburg tests would be positive in the following conditions:

A. L 4 LS PIVD
B. L5SI PIVD
C. Synovitis of the hip
D. Femoroacetabular impingement Syndrome

177. Identify the test being performed in the image below?

A. Trendelenburg
B. Thomas test
C. Smith
D. Narath

178. Spur sign is seen in:

A. Supracondylar fracture hummers
B. Bicolumnar Acetabular fracture
C. Fracture neck of femur
D. Radial head fracture

179. Pelvic fracture most serious complication is:

A. Hypovolemic shock
B. Neurogenic shock
C. Bladder injury
D. Pelvic instability

180. Morel –Lavallee lesion is seen in:

A. Acetabular fracture
B. Fracture femur neck
C. Fracture fracture
D. Fracture proximal tibia

181. True about Crescent fracture is:

A. Anteroposterior instability with rotational stability
B. Diastasis of pubis with pubic rami fracture
C. Antero-Posterior compression is the mechanism of injury
D. Fracture of the iliac bone with sacroiliac disruption

182. A 60- year – old female lands up in emergency with history of fall, the attitude of limb is extension and external rotation, the most probable diagnosis is:

A. Intracapsular fracture neck of femur
B. Posterior dislocation of hip
C. Intertrochanteric fracture
D. Acetabulam fracture

183. The commonest hip injury in the elderly patients is:

A. Stress fracture
B. Extracapsular fracture
C. Impacted fracture neck of femur
D. Sub capital capsular fracture neck of femur

184. 80 years old female after fall developed inability to walk with external rotation deformity on examination. SLR is not possible and broadening of trochanter is present. The possible diagnosis is:

A. Fracture neck femur
B. Fracture intertrochanteric femur
C. Fracture subtrochanteric femur
D. Fracture greater trochanter

185. Which of the following fractures of the neck of femur are associated with maximal compromise in blood supply?

A. Intertrochanteric fractures
B. Basicervical fracture
C. Trans cervical fracture
D. Subcapital fractures

186. Not a complication of fracture neck of femur:

A. Non –union
B. Malunion
B. AVN
D. Osteoarthritis

187. Most common complications of intertrochanteric fracture femur is

A. Malunion
B. Non – union
B. Osteoarthritis
D. Nerve injury

188. The most common type of hip fracture in childhood is:

A. Intertrochanteric
B. Transcervical
C. Transphyseal (through head)
D. Subcapital

189. Mcmurray's osteotomy is done for:

A. Malunited intertrochanteric fracture of femur
B. Non –union transcervical neck fracture of femur
C. Non –union lateral condyle fracture of humerus
D. Malunited supracondylar fracture of humerus

175. a	176. a	177. b	178. b	179. a	180. a	181. d	182. a	183. b	184. b	185. d
186. b	187. a	188. b	189. b							

190. Garden -1 fracture are also known as:

A. Complete fracture without displacement
B. Complete fracture with minimal (Partial) displacement
C. Complete fracture with full displacement
D. Valgus impaction fractures

191. In fracture neck femur all the trabeculae of pelvis and femur are in alignment in which stage:

A. Stage I
B. Stage II
C. Stage III
D. Stage IV

192. Fracture neck of femur in 80 year old male sustained 1 week back, The treatment of choice is:

A. Hemiarthroplasty
B. Excision Arthroplasty
C. Closed reduction and fixation with three cancellous screws
D. Longitudinal skin traction for 6 weeks.

193. fracture neck of femur in a 40-year –old male presenting after 2 days.

A. Hemiarthroplasty
B. Closed reduction and internal fixation by cancellous screws
C. Closed reduction and internal fixation by Austin moore pins.
D. Plaster and rest

194. Trochanteric fracture of femur is best treated by:

A. Dynamic hip screw
B. Inlay plates
C. Plaster in abduction
D. Plaster in abduction and internal rotation

195. A Patient presented after RTA with following attitude of the limb. What may be the most possible diagnosis?

A. Posterior dislocation of hip
B. Anterior dislocation of hip
C. Central dislocation of hip
D. Lateral dislocation of hip

196. All of the following is true about dashboard injury except:

A. It is associated with posterior dislocation of the hip
B. Sciatic nerve may be involved leading to foot drop
C. Avascular necrosis of the hip could be a late complication
D. The point of impact is on the greater trochanter

197. Type of injury in this case:

A. Posterior dislocation of hip
B. Anterior dislocation of hip
C. Central dislocation of hip
D. Lateral dislocation of hip

198. Pipkin's classification system is used for

A. Fracture femur head
B. Fracture femur shaft
C. Fracture proximal tibia
D. Fracture calcaneum

199. Posterior dislocation of hip can damage which nerve:

A. Superior gluteal
B. Sciatic
C. Inferior gluteal
D. Femoral

200. Vascular sign of Narath is positive in

A. Anterior hip dislocation
B. Posterior hip dislocation
C. Anterior shoulder dislocation
D. Posterior shoulder dislocation

201. Maximum shortening of limbs occur in

A. Intertrochanteric fracture femur
B. Posterior dislocation of hip
C. Fracture neck femur
D. Anterior dislocation of hip

190. d	191. b	192. a	193. b	194. a	195. b	196. d	197. c	198. a	199. b	200. b
201. b										

Pelvis — Explanations

175 A. Shoemakers line

Nelatons line is marked from ischial tuberosity to ASIS, Galleazi test done with both knee flexed, Thomas test with the hip flexed.

176. A. L4 L5 PIVD

- Disc prolapse at L4-5 compresses L5 nerve root which supplies gluteus medius and minimus.

177. B. Thomas test

Thomas' test is done to measure/reveal fixed flexion deformity of hip by neutralising lumbar lordosis. Patient is asked to flex the sound hip to reveal deformity in unsound hip. Trendelenburg test is done with the patient standing on sound leg, with the affected leg/hip off the ground.

178. B. Bicolumnar Acetabular fracture

Spur sign, seen on Xray is a diagnostic sign of bicolumnar fracture acetabulum.

179. A. Hypovolemic shock

Fracture pelvis can lead to maximum blood loss and thus hypovolemic shock.

180. A. Acetabular fracture

Morel-Lavalle lesion. It is mostly seen in pelvic & acetabular fracture and the M/c site is around the greater trochanter in anterolateral thigh.

181. D. Fracture of the iliac bone with sacroiliac disruption

Crescent fracture is the fracture of ilium bone involving the SI joint.

182. A. Intracapsular fracture neck of femur

- Fracture NOF is a low energy trauma, occurring in elderly population with shortening, ER attitude of the limb.
- Fracture I/T femur is a relatively higher energy trauma, occurring in adult (high energy)/old population (Low energy), with same but more prominent deformities compared to # NOF.
- Posterior hip dislocation –Flexion & IR attitude of hip.

183. B. Extracapsular fracture

184. B. Fracture intertrochanteric femur

80 years old female, low energy trauma with ER deformity – D/D : # NOF and # I/T femur. But broadening of trochanter point towards fracture I/T femur.

185. D. Subcapital fractures

Maximal comp/romise of blood supply, i.e more chances of AVN : Subcapital > trans cervical, Basi cervical fracture NOF.

186. B. Malunion

Mal-union is not a complication of # NOF, however Non-union is a common complication. Malunion is M/C complication of I/T femur fracture.

187. A. Malunion

Mal-union is a common complication of # I/T femur owing to its cancellous location.

188. B. Transcervical

Transphyseal – Rare & worst prognosis, Transcervical – M/C type.

189. 'B' Non –union transcervical neck fracture of femur

Mcmurray's osteotomy is done for fracture non-union # NOF, to give it a biomechanical advantage.

190. D. Valgus impaction fractures

Garden type I is an incomplete fracture (valgus impacted)
Complete fracture w/o displacement – type II, partial displacement – type III, full displacement –type IV.

191. B. Stage II

Garden type I is an incomplete fracture (valgus impacted)
Complete fracture w/o displacement – type II, partial displacement – type III, full displacement –type IV.

192. A. Hemiarthroplasty

In fracture NOF in older population, treatment protocol is;

- >60 years / active / long life expectancy / arthritic changes present – TOC is THR
- >60 years/ less active / life expectancy is less / no arthritic changes - than a smaller procedure like hemihip arthroplasty can be done.

193. B. Closed reduction and internal fixation by cancellous screws

Adult population - CRIF with CCS (3 screws in inverted triangle pattern) is the TOC in fresh cases (<3weeks). Hemiarthroplasty is done in older population with less life expectancy.

194. A. Dynamic hip screw

195. B. Anterior dislocation of hip

The attitude of limb is flexion, abduction & external rotation, s/o anterior dislocation of hip.

196. D. The point of impact is on the greater trochanter

The point of impact is on the knee. Injury in a flexed hip & knee producing posterior fracture dislocation of hip, patella fracture and PCL injury. Since posterior dislocation, it may be associated with sciatic nerve injury & AVN

197. C. Central dislocation of hip

The xray is s/o central hip dislocation, with femoral head crossing the acetabular floor to the pelvic cavity on left side. Anterior / posterior dislocation are a/w ER/IR deformity.

198. A. Fracture femur head

Fracture SOF – Winquist classification, Proximal tibia – Schatzker classification & calcaneal fracture –Sanders classification.

199. B. Sciatic

Sciatic nerve is the most commonly injured nerve in posterior hipdislocation.

200. B. Posterior hip dislocation

Vascular sign of Narath deals with femoral pulse. It is positive when femoral bed for femoral pulse palpation is absent l/t absent femoral pulse and is seen in posterior hip dislocation.

201. B. Posterior dislocation of hip

Fracture NOF and I/T femur fracture also l/t shortening of limb, but maximum shortening is seen in posterior hip dislocation. Shortening:

Posterior hip dislocation > # SOF > # S/T femur > # I/T femur > # NOF.

202. Denis gave how many theory to define stability of spine:

A. 1
B. 2
C. 3
D. 4

203. The commonest cause of spinal cord injuries in our country is:

A. Road traffic accident
B. Fall from a height
C. Fall into well
D. House collapse

204. Full from of SCIWORA

A. Stellate fracture across base of skull
B. Spinal cord injury without radiological
C. Spinal cord involvement with radiological abnormality
D. Spinal cord injury without radiological abnormity

205. Dislocation without fracture is seen is:

A. Sacral spine
B. Lumbar spine
C. Cervical spine
D. Thoracic

206. The compression fracture is commonest in:

A. Cervical spine
B. Upper Thoracic spine
C. Lower thoracic spine
D. Lumbosacral region

207. All the following are true about fracture of the atlas vertebra, except:

A. Jefferson fracture is the most common of atlas.
B. Quardriplegia is seen in 80 % cases.
C. Atlantoocipital fusion may sometimes be needed.
D. CT scan'sshould be done for diagnosis.

208. 'Whip –lash' injury is caused due to:

A. A fall from a height
B. Acute hyperextension of the spine
C. A Blow on top head
D. Acute hyper flexion of the spine.

209. The following X-ray was taken of a 50-years – old female with chronic backache. What is the most likely diagnosis?

A. Spondylolysis
B. Spondylosis
C. Spondylosthesis
D. Prolapsed inter-vertebral disc

210. Spot the xray sign shown here:

A. Beheaded Scottish terrier dog sign
B. Inverted Napoleon hat sign
C. Dumb bell sign
D. None

211. Spondylosthesis most common level:

A. L4-L5
B. L5-S1
C. C5-C6
D. C6-C7

212. A patient involved in a road traffic accident present with Quadriparesis, sphincter disturbance, sensory level up to the border of sternum and respiratory rate of 35/ minute. The level of lesion is :

A. C1 –C2
B. C4 -C5
C. T1 –T2
D. T3 –T4

213. A 40 year old male after RTA, attains spinal injury. His lower limb power is greater than that of upper limb and sacral sensation are present. Type of spinal cord lesion is:

A. Central cord syndrome
B. Anterior cord syndrome
C. Posterior cord syndrome
D. Complete cord syndrome

214. Complete transaction of the spinal cord at the C7 level produces all of the following effects except:

A. Hypotension
B. Limited respiratory effort
C. Anaesthesia below the level of the lesion
D. Areflexia below the level of the lesion

215. A patient presented with saddle anaesthesia, bladder and bowel are normal and muscle power is normal, the diagnosis is:

A. Cauda equina syndrome
B. L3- L4 root involvement
C. Cronus modularise lesion
D. L-4 L-5 Disc prolapsed

202. c	203. b	204. d	205. c	206. c	207. b	208. b	209. c	210. a	211. b	212. b
213. a	214. d	215. c								

216. All of the following are red flag sign of back pain except:

A. Previous history of malignancy
B. Previous History of steroid use
C. Saddle aneasthsia
D. Age between 35-50

217. Removal of vertebral disc is by all these methods except:

A. Laminotomy
B. Laminectomy
C. Laminoplasty
D. Hemilaminectomy

218. Lumbar canal stenosis presents as:

A. Claudication
B. Scoliotic deformity
C. Kyphotic deformity
D. Radiculopathy

219. Disc prolapsed is M/C in lumber spine, due to:

A. Less hydrated
B. Posterior nucleus pulposus
C. Weak ligamentum flavum
D. More degenerative forces

220. Most common site for lumbar disc prolapsed:

A. L4-L5
B. L5-S1
C. L1-L2
D. L3-L4

221. L4-L5 disc prolapse compresses commonly:

A. L_3
B. L_4
C. L_5
D. S_1

222. Substance that is used for verterbroplasty is :

A. Polymethyl methacrylate
B. Polyethyl methacrylate
C. Polymethylethacrylate
D. Polyethylethacrylate

223. Name the procedure done here:

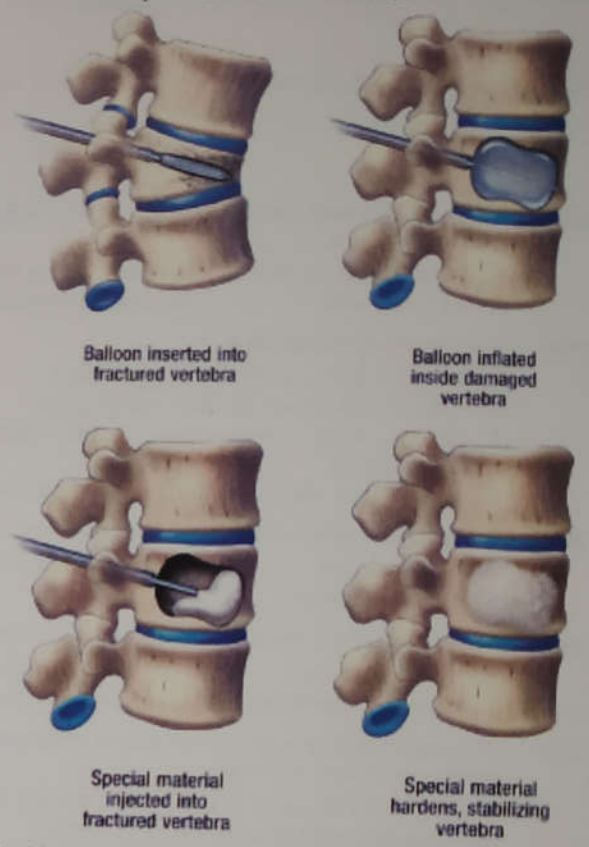

A. Vertebroplasty
B. Kyphoplasty
C. Both correct
D. None

224. Percutaneous vertebroplasty is not done for:

A. TB
B. Osteoporosis
C. Haemangioma
D. Metastasis

216. d	217. c	218. a	219. a	220. a	221. c	222. a	223. b	224. a

Spine — Explanations

202. C. 3

[illegible]

203. B. Fall from a height

[illegible]

204. D. Spinal cord injury without radiological abnormality

- [illegible]

205. C. Cervical spine

- [illegible]

206. C. Lower thoracic spine

- [illegible] axial load injuries [illegible] the most common site of [illegible] the thoracolumbar junction

207. B. Quardriplegia is seen in 80 % cases

- [illegible] being very wide in C1-C2 region, [illegible] this region, rarely results in [illegible]

208. B. Acute hyperextension of the spine

- [illegible] occurs when hit by rear vehicle [illegible] sudden unexpected hyperextension [illegible] spine followed immediately by flexion

209. C. Spondylosthesis

[illegible] spondylolisthesis of L5 vertebrae [illegible] is degenerative spine, and [illegible] in pars without displacement

210. A. Beheaded Scottish terrier dog sign

[illegible] view showing the Beheaded [illegible] terrier dog sign

211. B. L5-S1

- [illegible] level of spondylolisthesis is L5-S1
- [illegible] level of degenerative spondylolisthesis is L4-L5

212. B. C_4-C5

- C3 — sensory supply to lower part of neck, till clavicle
- C4 — sensory supply to subclavicular region/upper part of sternum
- Phrenic nerve (C3-5) supplies diaphragm
- Thus lesion at C4-5 will cause above mentioned symptoms.

213. A. Central cord syndrome

In Central cord syndrome, UL involvement is more than L/L, motor impairement is more than sensory. Whereas in anterior cord syndrome, motor is predominantly involved and in posterior [illegible] sensory is [illegible]

214. D. Areflexia below the level of the le[illegible]sion

- [illegible] aphragm is [illegible] with major [illegible] s spared in [illegible] es supplied [illegible] lved. Deep [illegible] ion will be [illegible]

215. C. conusmedullaris syndrome

- [illegible] anaesthesia [illegible] gth largely.

216. D. Age between 35-50

[illegible] d flad signs [illegible]

217. C. Laminoplasty

- Lamina is either [illegible] ninectomy) or opened. Laminotomy [illegible] roach the intervertebral disc

218. A. Claudication

PIVD presents as radiculopathy, [illegible] as lumbar canal stenosis presents as claudication

219. A. Less hydrated

PIVD is M/C at lumbar spine [illegible] l spine. In lumbar spine, disc is less hydrated [illegible] ng it more vulnerable to prolapse

220. A. L4-L5

L4-L5 > L5-S1 is the M/C site [illegible] mbar disc prolapsed

221. C. L5

- For Lumbar disc (with eg of L4-L5 [illegible] erniation):
  - Central (para-central lumbar disc) (eg: L4-L5 disc). Cause exiting nerve root sy[illegible] ptoms i.e. the one below (eg L5 nerve root)
  - Far lateral (foraminal disc) (eg: L4-L5 disc) Causes traversing nerve root co[illegible] mpression symptoms (eg L4 nerve root)

222. A. Polymethyl methacrylate

Polymethyl methacrylate is the bone ceme[illegible] t used in vertebroplasty

223. B. Kyphoplasty

Percutaneous injection of bone cement into collapsed vertebral body

- Vertebroplasty
- Kyphoplasty (via balloon) (safe and sup[illegible] erior due to no leakage/extravasation)

224. A. TB

In any infective procedure, vertebroplasty [illegible] s contra-indicated

225. Identify the use of the instrument?



A. Lumbar traction
B. Cervical traction
C. Tibia traction
D. Femur traction

226. Weight allowed in skeletal traction up to:

A. 5kg
B. 10kg
C. 20kg
D. 30kg

227. Cast syndrome is a complication of:

A. Hip spica
B. Below elbow cast
C. Above elbow case
D. PTB cast

228. Which of the following casts/splints is used for fracture shaft humerus?

A. Hanging casts
B. Knuckle bender splint
C. Aeroplane splint
D. Above elbow cast

229. What about Denham pin is true:

A. It is used to give skeletal traction
B. It has threads in the center of pin
C. It is used to give skeletal traction through calcaneum
D. All of the above

230. Commonest indication for ankle arthrodesis is:

A. Rheumatoid arthritis
B. Post-traumatic arthritis
C. Post infective arthritis
D. Failed total ankle arthroplasty

231. Functional bracing is now the gold standard in nonoperative management of which fractures?

A. Fracture shaft humerus
B. Fracture of both bones of the forearm
C. Fracture shaft tibia
D. Fracture shaft femur

232. Traction not used in lower limb:

A. Gallows
B. Bryant
C. Dunlop
D. Perkin

233. Functional cast bracing not used in fracture of:

A. Humerus
B. Tibia
C. Ulna
D. Thoracolumbar spin

234. Which is not a deep heat therapy:

A. Shortwave diathermy
B. Ultrasound therapy
C. Infrared therapy
D. Microwave therapy

235. Most common bone for which nailing is done?

A. Radius
B. Ulna
C. Tibia
D. Humerus

236. Action of intramedullary 'K' nail is:

A. Two-point fixation
B. Three-point fixation
C. Compression
D. Weight concentration

237. Which area of orbit is most commonly fractured in blown out fracture?

A. Roof
B. Floor
C. Medial wall
D. Lateral wall

238. True about lunate dislocation?

A. lunate dislocates anteriorly, while other carpal bones remains in place.
B. lunate stays in place while other carpal bones dislocates posteriorly.
C. More common than perilunate dislocation
D. None

225. b	226. c	227. a	228. a	229. d	230. b	231. a	232. c	233. d	234. c	235. c
236. b	237. b	238. a								

225. B Cervical traction.

For traction on tibia / femur, Steinman's pin is used and for lumbar traction traction belts/kit is used. The image shown is k/a Crutchfields tong used for cervical traction.

226. C. 20kg

Skeletal traction – applied when mod-severe force is required, with max weight permitted is upto 20kgs (upto 25-30% body weight.

227. A. Hip spica

Hip spica or scoliosis cast can press on superior mesenteric artery compressing 3rd part of duodenum known as cast syndrome. However, all types of cast can complicate into compartment syndrome if applied in acute injury / presence of swelling.

228. A. Hanging casts

Knuckle bender splint- For median / ulnar nerve palys

Aeroplane splint- For brachial plexus injury.

229. D. All of the above

Denham pin has threads at the centre of pin and is used to give skeletal traction in cancellous/ osteoporotic bones.

230. B. Post-traumatic arthritis

All can be an indication of ankle arthrodesis, but the commonest being post traumatic arthritis.

231. A. Fracture shaft humerus

Fracture shaft humerus is M/C managed conservatively, with sarmiento cast bracing/ PVC functional brace. While all other mentioned options are managed surgically.

232. C. Dunlop

Dunlop traction is used in supracondylar fracture humerus while Gallows / Bryants for # SOF (Child <2 yrs age) and Perkins for adult # SOF.

233. D. Thoracolumbar spine.

Thoracolumbar spine fracture are mostly managed surgically, while Tibia (PTB cast) and Ulna /humerus (sarmiento) can be managed with functional cast bracing.

234. C. Infrared therapy

Infrared therapy is a form of superficial heat therapy while, all other mentioned options are forms of deep heat therapy.

235. C. Tibia

Radius / ulna fracture are M/C managed surgically by plating and humerus by functional cast bracing.

236. B. Three- point fixation

K-Nail acts by the principle of 3-point bony fixation, at the two ends and at the isthmus.

237. B. floor

Inferior blow-out fractures (orbital floor) are the most common. Orbital fat prolapses into the maxillary sinus and may be joined by prolapse of the inferior rectus muscle. In children, the fracture may spring back into place (see trapdoor fracture). Most fractures occur in the floor posterior and medial to the infraorbital groove. Medial blow-out fractures are the second most common type.

238. A. lunate dislocates anteriorly, while other carpal bones remains in place

Wrist dislocations

Types-

- Lunate dislocation – lunate dislocates anteriorly, while other carpal bones remains in place.
- Perilunate dislocation – lunate stays in place while other carpal bones dislocates posteriorly.

Perilunate dislocation is the more common type, & when it is associated with fracture scaphoid, it is known as trans scaphoid perilunate fracture dislocation. Median nerve is the M/C nerve injury in lunate / perilunate dislocation.

Xray –

- Disruption of gilula's line.
- Scapholunate dissociation (scapholunate ligament) produces "Terry Thomas sign".
- Lunate dislocation – "spilled tea pot sign" and "piece of pie sign".

Treatment – CR and fixation by K wires. Reduction is done by "Tavernier's maneuver".

Amputation — Questions

239. Which of the following is the ideal length of bone for a below knee stump

A. 12.5 cm to 17.5 cm
B. Less than 5 cm long
C. 7.5 cm to 10 cm long
D. 20 cm long

240. Best treatment modality for post amputation neuroma is?

A. Compression bandage
B. Ultrasound
C. Infrared
D. Interferential therapy

241. An amputation through fore arm where you make a fork of the two fore arm bones is is k/a

A. Chopart's amputation
B. Krukenberg amputation
C. Pirogoff amputation
D. Syme's amputation

242. Energy consumption in an above knee amputation is approximately

A. 20 %
B. 40%
C. 55%
D. 65%

243. Regarding SACH foot, all are true except?

A. Solid ankle cushion heel
B. Prosthesis
C. Squatting is easy
D. Does not look like a normal foot

244. Myodesis is employed in amputations for all of the following indications except

A. Trauma
B. Tumor
C. Children
D. Ischemia

245. Amputation is often not required in?

A. Gas gangrene
B. Buerger's disease
C. Chronic osteomyelitis
D. Diabetic gangrene

246. Jaipur foot was invented by?

A. B.L.Sehgal
B. P.K.Sethi
C. Rajnath
D. S.K.Verma

247. Principle of TENS for alleviating pain arounds joints and nerve?

A. Referred pain
B Gate control theory of pain
C. Interferential therapy
D. Compresssion bandage.

239. a	240. d	241. b	242. d	243. c	244. d	245. c	246. b	247. b

Amputation — Explanations

239. A. 12.5 cm to 17.5 cm

- Below knee amputation: Ideal length of stump is 15 cm from the medial joint line (ideally at the musculotendinous junction of gastrocnemius)

240. D. Interferential therapy

TENS > Interferential therapy are the most preferred therapy for post – amputation neuroma.

241. B. Krukenberg amputation

All other mentioned options are ankle and foot amputation.

242. D. 65%

Energy expenditure with amputation at various levels is inversely proportional to length of remaining limb

- Long below knee amputation: 10%
- Medium below knee amputation: 25%
- Short below knee amputation: 40%
- Average above knee amputation: 65%
- Hip disarticulation: 100%

243. C. Squatting is easy

SACh fot has a solid ankle cushion heel which inhibits active plantar/dorsiflexion of ankle and thus squatting is not possible with SACH foot, but possible with Jaipur foot.

244. D. Ischemia

Myodesis is contraindicated in patients with severe limb ischemia (e.g. PVD) because increased tension in muscle will further deteriorate vascularity.

245. C. chronic osteomyelitis

Its a relative/rare indication for amputation, while all others are absolute indication.

246. B. P.K.Sethi

247. B. Gate control theory of pain

TENS is most preferred and works by inhibiting pain gate pathway (TENS > Interferential therapy > USG).

248. A politician was shot by a gun in back in political rally at T8 level, after which he developed paraplegia. The fact that the injured nerve is not able to regenerate is due to all the reasons except:

A. No endoneurial tube
B. Glial scar formation
C. Absence of growth factor
D. Lack of myelin inhibitors

249. Post injection palsy is:

A. Neurotmesis
B. Neuropraxia
C. Axonotmesis
D. None

250. Seddon's Classification all are true except:

A. Complete anatomic division of nerve is classified Neurotmesis
B. Axonotmesis has Tinelis sign positive and progressive
C. Neurotmesis has complete recovery with/without surgical intervention
D. Saturday Night palsy involves radial nerve

251. Nerve Biopsy in leprosy is usually taken from:

A. Ulnar
B. Median
C. Lateral Popliteal
D. Sural

252. Tendon most commonly used for tendon transfer?

A. Palmaris Longus
B. Flexor Carpi Ulnaris
C. Patellofemoral tendon
D. Gracialis

253. Tinel's sign is used for:

A. To assess the severity of damage of nerve
B. To classify the type of nerve injury
C. To locate the site of nerve injury
D. To assess the recovery

254. Which of the following is true about nerve injury?

A. In all cases of open wound with clinical signs of nerve injury, nerve exploration should always be done.
B. Nerve conduction velocity is best predictor within 48 hrs of injury.
C. Positive Tinel's sign indicates the accurate location of lesion.
D. Traction nerve injury should be repaired immediately.

255. Prognosis after secondary nerve suturing is better in pure than in mixed ones. Based on this criterion, which one of the following nerves should be given the best result after suturing in identical conditions?

A. Common Peroneal nerve
B. Radial Nerve
C. Ulnar Nerve
D. Median Nerve

256. A pole vaulter had a fall during pole vaulting and had paralysis of the arm. Which of the following investigations gives the best recovery prognosis.

A. Electromyography
B. Muscle Biopsy
C. Strength Duration Curve
D. Creatine Phosphokinase levels

257. A patient after sleeping on chair with arm hanging whole night, presents with weakness in muscles supplied by ulnar nerve, causing claw hand. It is managed by:

A. Electrophysiological studies
B. Knuckle bender splint and wait and watch
C. Exploration of the nerve
D. Tendon Transfer

258. Which of the following deformity is evident in case of Erb's palsy?

A. Policeman tip deformity
B. Winging of Scapula
C. Claw hand
D. Wrist Drop

259. All are true regarding brachial plexus injury, except:

A. Preganglionic lesions have a better prognosis than postganglionic lesions
B. Erb's palsy causes paralysis of the abductors and external rotators of the shoulder
C. In Klumpke's palsy, Homer's syndrome may be present on the ipsilateral side
D. Histamine test is useful to differentiate between the preganglionic and postganglionic lesions.

260. Muscles paralysed in Erb's paralys are all except:

A. Biceps
B. Triceps
C. Brachioradialis
D. Brachialis

261. A 45 year male with abrupt onset, pain, weakness, loss of contour of shoulder and wasting of muscle of arm on 5th day of tetanus toxoid immunization in deltoid. Likely cause is:

A. Radial nerve entrapment
B. Thoracic outlet syndrome
C. Brachial neuritis
D. Hysteria

262. Most common cause of neurological deficit in upper limb is:

A. Polio
B. Erb's palsy
C. C1-C2 dislocation
D. Fracture dislocation of cervical spine

263. Which of the following muscle is supplied by axillary nerve?

A. Teres minor
B. Teres Major
C. Supraspinatus
D. Infraspinatus

248. d	249. a	250. c	251. d	252. a	253. d	254. a	255. b	256. a	257. b	258. a
259. a	260. b	261. c	262. b	263. a						

264. Axillary Nerve Injury is least likely in:

A. Shoulder dislocation
B. Fracture proximal hummers
C. Intramuscular injection
D. Improper use of crutch

265. Which of the following nerve injury is most commonly associated with a humerus shaft fracture?

A. Radial nerve
B. Median nerve
C. Axillary nerve
D. Ulnar nerve

266. Martin Gruber anastomosis is between:

A. Median and ulnar nerve
B. Ulnar and radial nerve
C. Radial and median nerve
D. None

267. Wrist Drop is a feature of?

A. Superficial radial nerve
B. Posterior interosseous nerve palsy
C. High radial nerve palsy
D. Avulsion of triceps tendon

268. A 24- year old male presents with a humerus fracture as shown in the figure below which is the nerve likely to be involved by the fracture?

A. Ulnar
B. Radial
C. Medial
D. Musculocutaneous

269. A 45-year-old carpenter with a blunt trauma to his arm sustained a fracture following which he developed wrist drop, loss of extension at fingers and loss of sensations on the lateral aspect of the wrist joint. Which of the following is true?

A. Patient has an injury to the median nerve
B. He should have also lost extension of the forearm
C. Patient has injured the radial nerve in the spiral groove
D. There is combined involvement of the radial nerve and median nerve

270. Extensor Carpi Radialis Longus is:

A. Extensor and ulnar deviator of the wrist
B. Extensor and radial deviator of the wrist
C. Injured in posterior interosseous nerve injury
D. Weak extensor of the wrist

271. Which of the following is used as a substitute for wrist extensors in radial nerve palsy?

A. Pronator teres
B. Palmaris longus
C. Flexor digitorum superficialis
D. Flexor digitorum profundus

272. A person is not able to extend his metacarpophalangeal joint. This is due to injury to which nerve?

A. Ulnar nerve
B. Radial nerve injury
C. Median nerve injury
D. Post Interosseous nerve injury

273. Commonest cause of "Wrist Drop" is:

A. Intramuscular injection
B. Fracture humerus
C. Dislocation of elbow
D. Dislocation of shoulder

274. Wartenburg sign is seen in palsy of

A. Ulnar nerve
B. Median nerve
C. Radial nerve
D. Axillary nerve

275. Palmar Interossei are involved in:

A. Ulnar nerve injury
B. Radial nerve injury
C. Median nerve injury
D. Erb's palsy

276. Nail bed of index finger is supplied by:

A. Median Nerve
B. Ulnar
C. Palmar Branch of median nerve
D. Palmar branch of ulnar nerve

277. A patient can make his fist but unable to flex his index finger. Which nerve is affected in him?

A. Radial Nerve
B. Ulnar Nerve
C. Musculocutaneus Nerve
D. Median Nerve

278. Compression of a nerve within the carpal tunnel produces inability to:

A. Abduct the thumb
B. Adduct the thumb
C. Flex the distal phalanx of the thumb
D. Oppose the thumb

279. A patient complaints of flexion of inter – phalangeal joints and hyperextension of MCP of hands. He is most likely suffering from:

A. PIN palsy
B. Dupuytren's contracture
C. Claw hand
D. Erb's palsy

264. d	265. a	266. a	267. c	268. b	269. c	270. b	271. a	272. d	273. b	274. a
275. a	276. a	277. d	278. d	279. c						

280. Claw hand is also known as:

A. Intrinsic minus hand
B. Intrinsic plus hand
C. Extrinsic plus hand
D. Extrinsic minus hand

281. Ulnar paradox is seen in:

A. High ulnar nerve palsy
B. Low ulnar nerve palsy
C. Combined median and ulnar nerve palsy
D. Guyons canal entrapment of ulnar nerve

282. Fromet's Sign is seen in:

A. Ulnar nerve palsy
B. Median Nerve Palsy
C. Musculocutaneous nerve palsy
D. Posterior Interosseous nerve palsy

283. A patient presents with loss of sensation of ring and littler finger with wasting of hypothenar muscles. Where is the lesion:

A. Deep branch of ulnar nerve
B. Superficial branch of ulnar nerve
C. Ulnar nerve before division into deep and superficial
D. Median nerve

284. A patient with leprosy presents with clumsiness of hand. His ulnar nerve is affected. Clumsiness is due to palsy of which muscle?

A. Extensor carpi ulnaris
B. Abductor pollicis brevis
C. Opponens pollicis
D. Interosseous muscle

285. Injury to the common peroneal nerve at the lateral aspect of head of fibula results in all of the following except:

A. Weakness of ankle dorsiflexion
B. Foot drop
C. Loss of ankle reflex
D. Sensory impairment on lateral aspect of leg extending to the dorsum of foot

286. Most common cause of carpal tunnel syndrome:

A. Pregnancy
B. Idiopathic
C. Alcoholism
D. Occupational-Excessive use of vibration instruments

287. A person came with symptoms of tingling and burning sensation over his palm near base of his thumb. He will also have which symptoms?

A. Atrophy of hypothenar muscles
B. Paresthesia over lateral 3 fingers
C. Loss of adduction of thumb
D. Loss of opposition of thumb

288. Which of the following nerve is involved in 'pronator teres syndrome?

A. Median nerve
B. Ulnar nerve
C. Radius nerve
D. Anterior interosseous nerve

289. Durkan test is used in clinical diagnosis of

A. Carpal tunnel syndrome
B. Radial tunnel syndrome
C. Pronator syndrome
D. Any nerve injury

290. Kiloh nevin syndrome is entrapment neuropathy of:

A. Median nerve
B. Ulnar nerve
C. AIN
D. PIN

291. Cubital tunnel syndrome involves:

A. Median nerve
B. Ulnar nerve
C. Tibial nerve
D. Common peroneal nerve

292. Tarsal tunnel sydrome involves:

A. Lateral cutaneous nerve of thigh
B. Posterior tibial nerve
C. Common peroneal nerve
D. Sciatic nerve

293. MORTON'S NEUROMA is entrapment neuropathy of

A. plantar intermetatarsal nerve
B. posterior tibial nerve
C. superficial peroneal nerve
D. calcaneal nerve

294. A 45-year-old man presents with weakness, pain and fatigue in both lower limbs. He gives history of both limb paralysis 20 years back. What is the most probable diagnosis?

A. Polymyositis
B. Muscular dystrophy
C. Post-polio syndrome
D. Neuropathy

295. A 35/F hypothyroid on treatment complaints of heaviness and tingling in left index and middle finger the pain often increases in night and she often has to get up which of the following is not a clinical test for this condition?

A. Finkelstein test
B. Phalen's test
C. Tinel's sign
D. Tourniquet test

296. Thoracic Outlet Syndrome is best diagnosed by:

A. CT scan
B. MRI
C. Digital subtraction angiography
D. Clinical examination

297. In 3-year-child with polio paralysis, tendon transfer operation is done at:

A. 2 months after the disease
B. 2 years after the disease
C. 6-12 months after the disease
D. After skeleton maturation

280. a	281. b	282. a	283. c	284. d	285. c	286. b	287. b	288. a	289. a	290. c
291. b	292. b	293. a	294. c	295. a	296. d	297. b				

298. Sudden hyperflexion of thigh over abdomen (McRobert's procedure), which of the following nerve is commonly involved?

A. Common peroneal nerve
B. Obturator nerve
C. Lumbosacral trunk
D. Lateral cutaneous nerve of thigh

299. Test for tight iliotibial band is:

A. Ober's test
B. Osber's test
C. Simmand's test
D. Charnley's test

300. Obstetric nerve palsy associated in peurperium?

A. Median
B. Facial
C. Radial nerve
D. Femoral nerve

301. Most common nerve used for monitoring in anaesthesia response?

A. Ulnar
B. Median
C. Radial
D. Musculocutaneous

298. d	299. a	300. d	301. a

248. D. Lack of myelin inhibitors

All the above mentioned options inhibit nerve regeneration except lack of myelin inhibitors.

249. A. Neurotmesis

Most common nerve injury involved in intramuscular injection injury is sciatic nerve > radial nerve and the type of palsy is neurotmesis.

250. C. Neurotmesis has complete recovery with/ without surgical intervention

Neurotmesis never recovers completely.

251. D. Sural

Sural nerve is the M/Cnerve used for nerve biopsy.

252. A. Palmaris Longus

Palmaris longus is an appendicular tendon, not much useful and not always present in all person. Thus its removal does not result in any functional disability and is M/C used for tendon transfer.

253. D. To assess the recovery

Tinel's sign is used to assess the recovery after nerve injury, and more specifically it assess sensory recovery.

254. A. In all cases of open wound with clinical signs of nerve injury; nerve exploration should always be done.

Option A is true. Tinel sign is used for assessment of nerve recovery, NCV is not done within 10-14 days post injury and traction palsy is not repaired immediately.

255. B. Radial Nerve

Ulnar, median, CPN are all mixed nerves. Radial nerve is predominantly motor nerve and has the best prognosis after injury.

256. A. Electromyography

Muscle biopsy and CPK levels has no role in assessing nerve recovey. EMG is the best modality to assess and follow nerve recovery.

257. B. Knuckle bender splint and wait and watch.

It is a type of neuropraxia and almost always recovers automatically. During the period of recovery, the extremity is splinted in functional position to prevent any joint contractures.

258. A. Policeman tip deformity

Claw hand – ulnar nerve injury, winging of scapula – long thoracic nerve injury, wrist drop in radial nerve palsy.

259. A. Preganglionic lesions have a better prognosis than postganglionic lesions

Preganglionic injury is surgically irreperable and has the worst prognosis.

260. B. Triceps

Triceps is supplied by radial nerve, which is intact in Erb's palsy.

261. C. Brachial neuritis

Pain, weakness, muscle wasting points to nerve injury by injection.

262. B. Erb's palsy

Erb's palsy is the M/C cause of upper limb neurological deficit.

263. A. Teres minor

Axillary nerve supplies deltoid muscle and teres minor muscle.

264. D. Improper use of crutch

All other mentioned options are common causes of axillary nerve injury, while improper use of axillary crutch is less likely to injure axillary nerve.

265. A. Radial nerve

Radial nerve is the M/C nerve injury in humerus shaft fracture due to its anatomical predisposition in the spiral groove and crossing of the nerve from posterior to anterior compartment.

266. A. Median and ulnar nerve.

Anastomosis b/w ulnar nerve & median nerve k/a martin Gruber anastomosis & Riche cannieu anastomosis. In acse of nerve injury it can carry alternative conduit for signals.

267. C. High radial nerve palsy

PIN palsy will not result in wrist drop. It will result in finger drop.

268. B. Radial

The bony spike projecting laterally (k/a Holstein Lewis fragment) will injure the radial nerve, when it crosses posterior compartment to anterior.

269. C. Patient has injured the radial nerve in the spiral groove

Long & medial head of triceps are supplied before spiral groove, thus lesion at spiral groove will spare elbow extension.

270. B. Extensor and radial deviator of the wrist

ECRL is supplied by radial nerve after emerging from spiral groove in the arm, and is a wrist extensor and radial deviator.

271. A. Pronator teres

- Pronator teres to ECRL/ECRB -> wrist extensors
- FCU to EDC -> finger extensors
- FCR to EPL -> thumb extension.

272. B. Radial nerve injury, D. Post Interosseous nerve injury

PIN supplies all extensor muscles of wrist & hand except ECRL (Radial nerve) & lumbricals/interossei (Median/ulnar nerve).

PIN palsy presents with only loss of extension of MCP joint without loss of extension of wrist & IP joint (lumbricals /interossei) & there is no sensory loss.

273. B. Fracture humerus

Wrist drop is due to radial nerve and fracture humerus is the M/C cause of radial nerve palsy.

274. A. Ulnar nerve.

Wartenburg sign weakness of little finger adduction and is held in abducted position at rest, a sign, seen in ulnar nerve palsy.

275. A. Ulnar nerve injury

Palmar / dorsal interossei – Ulnar nerve, Median nerve supplies 1st / 2nd lumbricals.

276. A. Median Nerve

- Median nerve - Sensory
  - Palmar-lateral half of palm, lateral 3n half finger
  - Dorsal- Distal part of lateral 3 n half finger.

277. D. Median Nerve

This is pointing index, seen in median nerve injury.

278. D. Oppose the thumb

Abductor pollicis – radial nerve, adductor pollicis - ulnar nerve, FPI – median nerve (AIN) in forearm.

279. C. Claw hand

This is claw hand, seen in ulnar nerve palsy.

280. A. Intrinsic minus hand

Since intrinsic muscles are paralysed in claw hand, it is aka intrinsic minus hand.

281. B. Low ulnar nerve palsy

Ulnar paradox- in low ulnar nerve palsy forearm muscles are spared but the clawing is more (as compared to high ulnar nerve palsy) because in low ulnar nerve palsy finger flexors are spared which adds on to the deformity by flexing IP joints.

282. A. Ulnar nerve palsy

Positive book test/ Fromet sign – d/t weakness of adductor pollicis patient holds book b/w thumb & index finger by using FPL (i.e there is flexion of IP joint of thumb).

283. C. Ulnar nerve before division into deep and Superficial

Area involved is supplied by ulnar nerve and, as both sensory and motor component is involved, the area of lesion is before division into deep and superficial branch.

284. D. Interosseous muscle

Interosseous muscles are responsible for fine movements of hand, supplied by ulnar nerve. Thus interosseus muscle palsy leads to hand clumsiness.

285. C. Loss of ankle reflex

In CPN palsy, inversion & plantar flexion are normal and ankle reflex is preserved, an attitude l/t equino-varus.

286. B. Idiopathic

All the above mentioned options are causes of carpal tunnel syndrome, M/C being idiopathic.

287. B. Paresthesia over lateral 3 fingers

The clinical feature mentioned is of sensory involvement of median nerve, and median nerve also supplies lateral 3 & half fingers. It may be a case of carpal tunnel syndrome and in CTS motor involvement is very late.

288. A. Median nerve

It is the entrapment neuropathy of the median nerve in elbow.

289. A. Carpal tunnel syndrome.

Durkan test is the best test, used to diagnose carpal tunnel syndrome clinically.

290. C. AIN.

It is the entrapment neuropathy of AIN branch of median nerve.

291. B. Ulnar nerve

Cubital tunnel syndrome as the name suggests, it is disease of upper limb, involving ulnar nerve.

292. Tarsal tunnel sydrome involves:

A. Lateral cutaneous nerve of thigh
B. Posterior tibial nerve
C. Common peroneal nerve
D. Sciatic nerve

292. B. Posterior tibial nerve

It is analogous to carpal tunnel syndrome in the upper limb. The nerve involved is the posterior tibial nerve at the flexor retinaculum or the laciniate ligament

293. A. plantar intermetatarsal nerve

It is a benign neuroma of an intermetatarsal plantar nerve, most commonly of the second and third intermetatarsal spaces

294. C. Post-polio syndrome

The given history, with predominant motor involvement, with past history of palsy, is classical of post polio syndrome.

295. A. Finkelstein test

The clinical diagnosis here is – carpal tunnel syndrome, all other three mentioned options are used to diagnose CTS. Finkelstein test is used in De Quervain's tenosynovitis.

296. D. Clinical examination

TOS is best diagnosed clinically, no imaging investigation is as useful as clinical examination.

297. B. 2 years after the disease

- Tendon transfers are ideally done after 5 years of age, so that they can have compliance with physiotherapy exercises. As the child is 3 years old, tendon transfer should be done after 2 years (at 5 years of age).

298. D. Lateral cutaneous nerve of thigh

- McRoberts maneuver – femoral nerve > lateral cutaneous nerve of thigh.

299. A. Ober's test

Ober's test is the test used for ITB examination. Simmond's test is used for Achilles tendon rupture.

300. D. femoral nerve

Lower extremity nerves are mostly affected during childbirth. Lateral femoral cutaneous nerve isthe commonest nerve damaged during delivery and child birth process causing meralgia paraesthetica. Foot drop is also very common as both Sciatic nerve and CPN can be injured as well owing to the lithotomy position in obstetric procedures.

301. A. ulnar

Adductor pollicis supplied by 'Ulnar nerve' is the most commonly used to monitor anaesthesia response.

302. Gradual painful limitation of shoulder movement in an elderly suggest that the most probable diagnosis is:

A. Osteoarthritis
B. Periarthritis
C. Myositis ossifications
D. Fracture – dislocation

303. All of the following associated with frozen shoulder except:

A. Diabetes
B. Hyperthyroidism
C. Psoriasis
D. Hemiplegia

304. First movement to be restricted in frozen shoulder is:

A. Flexion
B. Extension
C. Internal rotation
D. External rotation

305. The posterolateral lesion in the head of humerus in cases of recurrent anterior shoulder dislocation is?

A. Bankart's lesion.
B. Hill- Sachs lesion.
C. Reverse Hill- Sachs lesion.
D. Greater tuberosity avulsion.

306. A 42- year-man is diagnosed to have irreparable tear of the rotator cuff. Treatment of choice will be?

A. Tendon transfer.
B. Total shoulder replacement.
C. Reverse shoulder replacement.
D. Acromioplasty.

307. A patient of recurrent anterior dislocation presents with the following xray, diagnosis is :

A. Bankart lesion
B. Hill sach's lesion
C. Fracture scapula
D. Reverse Hill sach's lesion

308. A patient of rotator cuff injury evaluated by the following test, muscle tested is:

A. Subscapularis
B. Supraspinatus
C. Biceps brachii
D. Infraspinatus

309. Putti Platt's operation involves tightening of which muscles?

A. Supraspinatus.
B. Subscapularis.
C. Infraspinatus.
D. Deltoid.

310. Following Defect (lesion) is NOT responsible for recurrent anterior dislocation of shoulder?

A. Bankat's lesion
B. Hill-Sachs lesion
C. Bristow's lesion
D. A defect in the anterior- inferior capsule

311. Recurrent dislocations are least commonly seen in?

A. Ankle
B. Hip
C. Shoulder
D. Patella

312. Lateral epicondylitis elbow begins in:

A. Flexor digitorum superficialis
B. Flexor digitorum profundus
C. Extensor carpi radialis longus
D. Extensor carpi radialis brevis

313. Cozen'stest is used for the diagnosis of:

A. Tennis elbow
B. Golfer's Elbow
C. Base bailer's pitcher elbow
D. Carpal tunnel syndrome

314. De Quevian's tenovaginitis involves tendons of:

A. 1st dorsal compartment
B. 2nd dorsal compartment
C. 3rd dorsal compartment
D. 4th dorsal compartment

315. Dupuytren's contracture is fibrosis of:

A. Palmar fascia
B. Firearm muscles
C. Sartorius fascia
D. None of the above

302. b	303. c	304. c	305. b	306. a	307. a	308. a	309. b	310. c	311. a	312. c
313. a	314. a	315. a								

316. The best treatment for Dupuytren's contracture is:

A. Fasciotomy
B. Fasciectomy
C. Incision and release
D. Subtotal fasciectomy + Skin transplantation

317. A 50-year-old diabetic/ alcoholic patient, presented with 15 degree flexion deformity of the little finger what is the most appropriate management.

A. Wait and watch
B. Subtotal fasciectomy
C. Total fasciectomy
D. Percutaneous fasciectomy

318. Trigger finger is:

A. A feature of carpal tunnel syndrome
B. Injury to fingers while operating a gun
C. Stenosis tenovaginitis of flexor tendon of affected finger
D. Any of the above

319. Most common cause of trigger finger:

A. Trauma
B. Alcohol
C. Smoking
D. Drug abuse

320. In trigger finger level of tendon sheath constriction is found at the level of:

A. Middle phalanx
B. Proximal interphalangeal joint
C. Proximal phalanx
D. Metacarpophalangeal joint

321. Pulley involved in trigger finger:

A. A1
B. A2
C. A3
D. A4

322. Compound palmar ganglion is:

A. Tuberculosis affection of ulnar bursa
B. Pyogenic affection of ulnar bursa
C. Non- specific of ulnar bursa
D. Ulnar bursitis due to conpound injury

323. Jersey finger is caused by rupture of:

A. Flexor digitorum profundus
B. Extensor digitiminimi
C. Flexor digitorum superficialis
D. Extensor indicis

324. Mallet finger is due to rupture of:

A. Central extensor slip of finger
B. Distal end of index extensor
C. Distal end of flexor digitorum profundus
D. None of above

325. A 30-year-old man involved in a fight, injured his middle finger and noticed slight flexion of DIP joint. X-rays were normal. The most appropriate management at this stage is:

A. Ignore
B. Splint the finger in hyperextension
C. Surgical repair of the flexor tendon
D. Buddy strapping

326. Game Keeper's thumb is:

A. Ulnar collateral ligament injury of MCP joint
B. Radial collateral ligament injury of MCP joint
C. Radial collateral ligament injury of CMC joint
D. Ulnar collateral ligament injury of CMC joint

327. No Man's land in hand surgery all are true except:

A. Results of flexor tendon repair are satisfactory in this area
B. Comprises zone II
C. Extends from distal palmar crease and flexor crease of PIP
D. Extends from distal palmar crease and insertion of flexor superficialis

328. All of the following are true about ACL except?

A. Prevents anterior motion of femur over tibia
B. Also provides secondary Varus- valgus stability
C. Is taught in extension of knee
D. It has two bundle – AM & PL.

329. Regarding Anterior Cruciate Ligament all are true expect?

A. Lachman test is the most sensitive test for ACL tear
B. Non contact pivoting injury causes ACL damage
C. Posterolateral bundle becomes taut in flexion
D. Almost always associated with meniscal tear
E. Is pathognomic of seagond's fracture

330. Muscle with intraarticular tendon?

A. Popliteus
B. Semimembranosus
C. Sartorius
D. Triceps

331. Which of the following is the SAFEST test to be performed in a patient with acutely injured knee joint?

A. Lachman's test
B. Pivot shift test
C. McMurray's test
D. Apley's grinding test

332. In "bounce home" test of knee 'end feels' are interference All are 'end feels' expect?

A. Firm
B. Sponge block
C. Empty
D. Bony

333. Lateral blow to knee with fracture in Intercondylar area structured injured is?

A. MCL
B. ACL
C. LCL
D. Menisci

334. Snapping knee syndrome is due to involvement of?

A. Pes Anserinus
B. Quadriceps Tendon
C. Gastrocnemius origin
D. Lateral collateral ligament

316. d	317. a	318. c	319. a	320. d	321. a	322. a	323. a	324. b	325. b	326. a
327. a	328. a	329. c	330. a	331. a	332. c	333. b	334. a			

335. Injury from lateral side of knee causes damage to?

A. MCL
B. LCL
C. ACL
D. PCL

336. A patient met with road traffic accident and developed knee pain. DIAL test was positive. Structure injured is?

A. Medial collateral ligament injury
B. Medial meniscal injury
C. Lateral meniscus tear
D. Posterolateral corner injury.

337. Which activity will be difficult to perform for a patient with an anterior cruciate deficient knee joint?

A. Walk downhill
B. Walk uphill
C. Sit cross leg
D. Getting up from sitting

338. Positive pivot shift test in knee is because of injury to?

A. Anterior cruciate ligament
B. Posterior cruciate ligament
C. Medial meniscus
D. Lateral meniscus

339. Which among the following is not a feature of Unhappy triad of O' Donoghue?

A. ACL injury
B. Medial meniscus injury
C. Medial collateral ligament injury
D. Fibular collateral ligament injury

340. A young boy presents with swollen knee, on getting hit over lateral aspect of knee and there was a twist while playing. Joint line tenderness was present. Anterior Drawer test done was negative. X-ray shows no fracture. Which structure is most likely to be damaged in the person?

A. ACL
B. Medial Meniscus
C. PCL
D. Lateral Meniscus

341. Patient presents with knee problem. He gives history of injury during playing hockey 3 months back. On testing knee was unstable anteriorly in extension but was stable in 90 degree of flexion. Probably injury involves?

A. ACL Anteromedial fiber
B. ACL Posterolateral fiber
C. PCL
D. Anterior Posterolateral fiber

342. Unlocking of knee is caused by:

A. Rectus femoris
B. Quadriceps
C. Hamstrings
D. Popliteus

343. Q angle is used for:

A. Knee
B. Hip
C. Elbow
D. Wrist

344. It is wise to keep and repair the meniscus rather than removing it when the injury is to which of the following?

A. Medial part of meniscus
B. Mid part of meniscus
C. Peripheral part of meniscus
D. Associated with collateral ligament injury

345. An athlete is sitting on the edge of table with knees flexed at 90 degree. When he extends his knee fully, what will happen to the tibial tuberosity in relation to patella?

A. No change
B. Movement of TT towards medial border of patella
C. Movement of TT towards lateral border of patella
D. Movement of TT towards center of patella

346. An 18-year-old boy was playing football, when he suddenly twisted his knee on the ankle and he fell down. He got up after 10min and again started playing, but next day his knee was swollen and he could not move it. The most probable cause is?

A. Medial meniscus tear
B. Anterior cruciate ligament injury
C. Medical collateral ligament
D. Posterior cruciate ligament

347. Olecranon bursitis:

A. Tennis elbow
B. Golfer's elbow
C. Student's elbow
D. Lesser leagues elbow

348. Bunion is commonly seen at:

A. Great toe MTP joint
B. Medial malleolus
C. Lateral malleolus
D. Shin of tibia

349. Ischial bursitis is also known as:

A. Clegyman's knee
B. Housernaid's knee
C. Weaver's bottom
D. Student's elbow

350. Site of TB bursitis:

A. Subacromial
B. Subdeltoid
C. Subpatellar
D. Trochanteric

351. Which of the following cysts is medially situated:

A. Housemaid's knee
B. Clergyman's knee
C. Bursa anserine
D. Morrant baker's cyst

352. The primary pathology in Athletic Pubalgia is?

A. Abdominal muscle strain
B. Recuts femoris strain
C. Gluteus medius strain
D. Hamstring strain

353. Commonest ligament injured in ankle injury?

A. Anterior talofibular ligament
B. Calcaneofibular ligament
C. Posterior talofibular ligament
D. Spring ligament

335. a	336. d	337. a	338. a	339. d	340. b	341. b	342. d	343. a	344. c	345. c
346. a	347. c	348. a	349. c	350. d	351. c	352. a	353. a			

354. A-23- year – old profession footballer suffered a twisting injury to his right ankle. On examination there is a lot of swelling around the medial malleolus but X- ray doesn't show any fracture. The structure injured could be?

A. Deltiod ligament
B. Anterior talofibular ligament
C. Spring ligament
D. Tendo Achilles

355. The most common site for ligamentous injuries are those of the?

A. Shoulder joint
B. Elbow
C. Knee joint
D. Ankle joint

356. All are the common sites of tendon rupture except?

A. Supraspinatus Tendon
B. Long head of biceps brachii
C. Achilles tendon
D. Extenson Hallucis longus tendon

357. Identify the abnormality shown in the following picture:

A. Hallux valgus
B. Hallux varus
C. Rheumatoid valgus
D. Subcutaneous nodule

358. A patient complains of pain in sole on prolonged standing with the following xray, diagnosis is:

A. Plantar fasciitis
B. Tarsal coalition
C. Ankylosing spondylitis
D. Calcaneal old healed fracture

359. K.L splint is used for:

A. Fracture tibia
B. Plantar fasciitis
C. De Quervain's tenosynovitis
D. Tennis elbow

360. Identify the abnormality shown in the following picture:

A. Hallux valgus
B. Hallux varus
C. Rheumatoid valgus
D. Hammer toe

354. a	355. d	356. d	357. a	358. a	359. b	360. d

302. B. Periathritis

The diagnosis here is of frozen shoulder / peri-arthritis. However, Myositis ossificans and fracture dislocation is not possible in absence of history of trauma. Osteoarthritis is less common in shoulder joint.

303. C. Psoriasis

Diabetes mellitus, hyperlipidemia, hyperthyroidism, dupuytren's disease, hemiplegia, etc are independent risk factors of frozen shoulder.

304. C. Internal rotation

Internal rotation followed by abduction.

305. B. Hill- Sachs lesion.

Hill Sach's lesion is contact /impression fracture of supero/postero- lateral humeral head in anterior shoulder dislocation. Bankart's is – injury to antero-inferior glenoid labrum.

306. A. Tendon transfer.

Irreparable tear is managed by tendon transfer. Treatment for shoulder arthritis is shoulder replacement but for rotator cuff arthropathy / dysfunctional deltoid with shoulder arthritis is "Reverse shoulder replacement".

307. A. Bankart lesion.

It is actually a type of "Bony bankart lesion".

308. A. Subscapularis

The test done is "Lift off test", where internal rotation of shoulder is tested, muscle involved is – subscapularis.

309. B. Subscapularis.

- Putti Plat's technique is done for recurrent dislocation of shoulder. Here joint is reinforced by overlapping and tightening subscapularis tendon with the capsule.

310. C. Bristow's lesion.

All other mentioned options are causes of recurrent anterior dislocation of shoulder.

311. A. Ankle

Ankle joint is among the least common joints for recurrent dislocation.
Overall least common dislocation is knee joint

312. C. Extensor carpi radialis brevis

Tennis elbow is chronic tendinitid of common extensor origin of elbow. Mainly it begins with microtear in the substance of ECRB origin.

313. A. Tennis elbow

314. A. 1st dorsal compartment.

Stenosing tenosynovitis of the abductor pollicis longus (APL) and extensor pollicis brevis (EPB) tendon (1st dorsal compartment).

315. A. Palmar fascia

It is proliferative fibroplasia of subcutaneous palmar tissue (palmar aponeurosis) in form of nodules and cord that may result in flexion contractures in fingers and palm.

316. D. Subtotal fasciectomy + Skin transplantation

Initially it can be managed conservatively with stretching exercise, but Subtotal fasciectomy + Skin transplantation is the best treatment.

317. A. Wait and watch

- Diagnosis is dupuytrens contracture. Surgical management is recommended when more than 30degree contracture is produced.

318. C. Stenosis tenovaginitis of flexor tendon of affected finger

It is a stenosing tenovaginitis of flexor tendon of the affected finger which may lead to entrapment of the tendon at A1 pulley at the level of MCP joint

319. A. Trauma

Causes : trauma, Rheumatoid arthritis, Gout, diabetes, etc.

320. D. Metacarpophalangeal joint

It is a stenosing tenovaginitis of flexor tendon of the affected finger which may lead to entrapment of the tendon at A1 pulley at the level of MCP joint.

321. A. A1

It is a stenosing tenovaginitis of flexor tendon of the affected finger which may lead to entrapment of the tendon at A1 pulley at the level of MCP joint.

322. A. Tuberculosis affection of ulnar bursa

Compound palmar ganglion is chronic inflammation of common sheath of flexor tendons above and below flexor retinaculum leading to an hour glass swelling. Rheumatoid arthritis and TB are common etiological factors.

323. A. Flexor digitorum profundus

Disruption of Flexor Digitorum Profundus (FDP) tendon from its insertion at the volar aspect of the distal phalanx is called jersey finger.

324. B. Distal end of index extensor

It is due to avulsion of extensor tendon from the base of dorsum of distal phalanx with or without a chip of bone.

325. B. Splint the finger in hyperextension

The diagnosis is mallet finger, managed by splintage in hyperextension.

326. A. Ulnar collateral ligament injury of MCP joint

Injury to thumb metacarpo-phalangeal joint ulnar collateral ligament.

327. A. Results of flexor tendon repair are satisfactory in this area

Results are not very good after reapir I this area, but due to recent advances, results are improving.

328. A. Prevents anterior motion of femur over tibia.

It prevents anterior motion of tibia over femur.

329. C. Posterolateral bundle becomes taut in flexion

ACL has two bundles : Antero-medial: tight in flexion and postero-lateral (Bulky), which is tight in extension. (Provides principal resistance to hyperextension).

330. A. Popliteus.

Popliteus has an intra-articular tendon, rest all are extra-articular.

331. A. Lachman's test

Lachman test is more sensitive & less painful to perform in acutely injured patient.

332. C. Empty

Bounce home test – knee is suddenly extended from flexed position and checked for the end point of extension. Normally it has hard(bony) or firm (cartilageneous) feel but in ACL/meniscal injury it gives rubbery feel.

333. B. ACL

- Fracture at Intercondylar which is the site insertion points towards ACL injury.

334. A. Pes Anserinus.

Pes is the conjoint tendon of – Sartorius, gracialis & semitendinosus. It might snap around the knee and cause snapping knee syndrome.

335. A. MCL.

Injury from lateral side causes valgus strain at knee l/t MCL injury.

336. D. Posterolateral corner injury.

Dial test is used for rotatory instability of knee, and tests competency of postero-lateral corner.

337. A. Walk downhill.

ACL injury – difficulty in walking downhill, PCL tear –difficulty in walking uphill.

338. A. Anterior cruciate ligament.

Tests in decreasing order of sensitivity and specificity for ACL : Lachman's test > flexion rotation drawer test > anterior drawer test > Pivot shift phenomena.

339. D. Fibular collateral ligament injury.

MCL and medial capsular ligament → ACL → Medial meniscus injury, known as unhappy triad of O'Donoghue.

340. B. Medial Meniscus

- Joint line tenderness is a good clue to medial meniscus injury.

341. B. ACL Posterolateral fiber

ACL has two bundles : Antero-medial: tight in flexion and postero-lateral (Bulky), which is tight in extension. (Provides principal resistance to hyperextension).

342. D. Popliteus

Locking of knee occurs as a result of medial rotation of femur during last 30° of extension (Quadriceps muscle) & Unlocking is by lateral rotation of femur over tibia in initial phase of flexion (Popliteus muscle).

343. A. Knee

Q angle is the measure of lateral pull at patella.

344. C. Peripheral part of meniscus

Peripheral part of meniscus is vascularised and has good chances of recovery. While medial part is less vascularised and carries poor prognosis even after repair.

345. C. Movement of TT towards lateral border of patella.

Open chain (I.e when foot is off the ground) : When the foot is off the ground and knee extends from flexion, tibia rotates externally and on flexion it rotates internally.

346. A. Medial meniscus tear

The typical history of knee twisting and delayed appearance of knee swelling is s/o meniscus injury.

347. C. Student's elbow

Golfer's elbow – common flexor origin, tennis elbow-common extensor origin, Little league elbow – valgus overload/ overstress to medial elbow.

348. A. Greater toe MTP joint

Bunion is seen in hallux valgus, where 1st MTP joint / MT head becomes prominent medially and prone to bursitis.

349. C. Weaver's bottom

Housemaids knee – Prepatellar bursitis, clergyman's knee – infrapatellar bursitis, Student's elbow – olecranon bursitis.

350. D. Trochanteric

TB bursitis – Most commonly involves trochanteric bursa > pes-anserinus bursa.

351. C. Bursa anserine

Housemaid – anteriorly, baker cyst – posteriorly, clergyman – inferiorly.

352. A. Abdominal muscle strain.

Rectus abdominis has its attachment atpubis. All other options can be ruled out considering their anatomical attachment.

353. A. Anterior talofibular ligament

Lateral ligament complex is the M/C injury, and in the complex- antero-talofibular ligament is the most commonly injured.

354. A. Deltiod ligament.

Deltoid ligament is attached at medial malleolus.

355. D. Ankle joint

Ankle sprain is the M/C ligament injury.

356. D. Extenson Hallucis longus tendon

Injury of EHL tendon is less commonly known.

357. A. Hallux valgus

Great toe is deviated outward k/a hallux valgus.

358. A. Plantar fasciitis

Pain in sole with a spur in calcaneum (seen in xray) is s/o plantar fasciitis.

359. B. Plantar fasciitis

Treatment : conservative (KL splint with rest, cold and NSAIDs -> steroid injection) and if not relieved than surgery.

360. D. Hammer toe

Flexion of PIP joint with extended DIP – Hammer toe
Flexion of DIP joint with extended PIP – Mallet toe.

Polytrauma — Questions

361. A 30 years male suffers from road traffic accident and a car runs over his right leg. On examination, vitals are stable. The right leg is crushed with exposed muscles and bones. The debate about limb survival can be resolved to an extent by MESS score which includes all except

A. B.P
B. Nerve injury
C. Velocity of trauma
D. Distal circulation

362. Permissible ischemia time for a proximal limb amputation is

A. 4 hours
B. 6 hours
C. 8 hours
D. 12 hours

363. Severely injured patient presents with spinal fracture and unconsciousness. First thing to be done is

A. GCS scoring
B. Spinal stabilization by cervical collar
C. Mannitol drip to decrease ICT
D. Airway maintenance

364. Which of the following is not a component of the crush syndrome?

A. Myo-hemoglobinuria
B. Massive crushing of muscles
C. Acute tubular necrosis
D. Bleeding diathesis

365. All of the following factors evaluate the chances of amputation in a limb, except

A. Age
B. B. P
C. Velocity of trauma
D. Presence of infection

366. Motorcyclist's fracture is

A. Ring fracture of base of skull
B. Comminuted fracture
C. A hinged fracture where the skull separates into anterior and posterior halves
D. Fracture base of skull

367. In cardiopulmonary resuscitation, the commonly fractured ribs are

A. 1st and 2nd
B. 3rd and 4th
C. 5th and 6th
D. 8th and 9th

368. Which of the following structures is fixed first during re-implantation of an amputated digit?

A. Bone
B. Artery
C Vein
D. Nerve

369. In crush injuries of hand the greatest priority is given to repair of

A. Tendons
B. Skin
C. Bone
D. Arteries

370. In shotgun injuries

A. Each and every shot should be removed
B. All the shots within accessible limits may be removed and thorough debridement of all the tissue is done
C. Shots lodged in joints must be removed
D. All the above are true

371. Following are principles in the treatment of compound fractures except

A. Wound debridement
B. Immediate wound closure
C. Tendon repair
D. Aggressive antibiotic therapy

372. What is the GCS of a patient presenting after injury, confused, eye opening on painful stimuli, flexion withdrawal on left side and pointing on right side?

A. 8
B. 9
C. 10
D. 11

373. Some patients present with injury in casualty. Which of these needs to be first evaluated by the orthopedician?

A. Decrease capillary refill in the fingers of the patient.
B. Fracture with intra articular extension
C. Patient with weakness of wrist extensors
D. Patient with abrasion >10cm over the fracture site.

374. Dequervain's disease is inflammation of?

A. Flexor pollicis longus
B. Abductor pollicis longus
C. ECRL
D. ECRB

375. In fasciotomy for compartment syndrome which structures are released?

A. Skin
B. Skin, subcutaneous tissue.
C. Skin, subcutaneous tissue, superficial fascia.
D. Skin, subcutaneous tissue, superficial fascia and deep fascia.

361. b	362. b	363. d	364. d	365. d	366. c	367. c	368. a	369. b	370. b	371. b
372. d	373. a	374. b	375. d							

361. B. Nerve injury

Nerve injury is not a component of MESS score.

362. B. 6 hours

Irreversible necrotic changes begin in muscles after 6 hours of ischemia (warm ischemia time), it is preferable to begin the re-implantation of parts with good muscular bulk (viz. parts proximal to palms and foot) within this time. With cooling (to 4°C), this time may be extended to 12 hours (cold ischemia time)

363. D. Airway maintenance

Concept behind ATLS is that save the life (i.e. prevent an impending cardiac arrest) by addressing the most dangerous threat to life first.

364. D. Bleeding diathesis

Massive crushing of muscle l/t myo-hemoglobinuria which in turn may lead to acute tubular necrosis. However, bleeding diathesis is not a feature of crush syndrome.

365. D. Presence of infection.

MES score which predicts salvagibility of limb in a patient of trauma, with a total score of 11.

	Score	
V- Velocity of trauma	1-4	VISA to death
I – Ischaemia	1-4	
S- Shock	0-2	
A – Age	0-1	
Total-	11	

Higher the score, higher are the chances of amputation, with a score of ≥ 7 leading to eventual amputation.

366. C. A hinged fracture where the skull separates into anterior and posterior

Motorcyclist fracture is a term given to hinged fracture where the skull separates into anterior and posterior halves.

367. C. 5th & 6th

The most commonly fractured ribs are 3rd and 4th.

368. A. Bone

Sequence of repair : BE FAN of Virat & Sachin : Bone, extensor tendon, flexor tendon, artery, nerve, Vein & Skin

369. B. Skin

But while the concerned digit/amputated part is addressed skin is preserved first, for adequate skin coverage for deeper structures and palmar skin is very important as its sensation is not reproducible by skin graft.

370. B. All the shots within accessible limits may be removed and thorough debridement of all the tissue is done.

Only accessible pellets should be attempted to remove, else more harm would be done than good in removing the pellets.

371. B. Immediate wound closure

Immediate wound closure is never the treatment protocol in compound/open fractures. Although with plastic surgery assistance, a skin graft/flap may be done at the same sitting after thorough wound debridement.

372. D. 11

GLASGOW CUMA SCALE	
Eye-opening (E)	
• Spontaneous	4
• To speech	3
• To pain	2
• Nil	1
Besl mator response (M)	
• Obeys	6
• Localises	5
• Withdraws	4
• Abnorm-ai tlexion	3
• Extern; or response	2
• Nil	1
Verbal response (V)	
• Orientated	5
• Confused conversation	4
• Inappropriate words	3
• Incomprehensible sounds	2
• Nil	1
Coma score = E + M + V	
• Minimum	3
• Maxirnum	15

373. A. Decrease capillary refill in the fingers of the patient

This is an emergency situation and needs to be evaluated first, as, if vascular injury is present, it needs to be managed within 6 hours.

374. B. Abductor pollicis longus

It is the inflammatory tenosynovitis of abductor pollicis longus and extensor pollicis brevis.

375. D. Skin, subcutaneous tissue, superficial fascia and deep fascia

Complete release of fascia is important to decompress the closed compartment of increased pressure.

376. Most common cause of osteomyelitis in sickle cell disease is

A. Salmonella
b. B. Staph aureus
C. Pseudomonas
D. Streptococcus pyogenes

377. Kanavel's sign are seen in

A. Tenosynovitis
B. Trigger finger
C. Carpal tunnel syndrome
D. Dupuytren's contracture

378. Most common organism causing infection after open fractures

A. Staphylococcus aureus B. Psudomonas
C. Klebsiella D. Gonococcus

379. Earliest change of osteomyelitis on X-Ray

A. Lytic defects
B. Loss of soft tissue planes
C. Sequestrum
D. Periosteal reaction

380. Most common joint involved in septic arthritis

A. Knee B. Shoulder
C. Hip D Elbow

381. Tom smith arthritis manifests as

A. Hip stiffness
B. Ankylosis
C. Lengthening of limb
D. Increased hip mobility & instability

382. A 30-year-old male, HIV positive, on antiretroviral therapy, has pain in right hip region. There is flexion, abduction and external rotation deformity of right hip since 2 months. Most likely diagnosis is

A. TB Hip
B. Avascular necrosis
C. Septic arthritis
D. Transient synovitis

383. Most common site of actinomycosis amongst the following is

A. Femur B. Mandible
C. Tibia D. Rib

384. Most common finger infected by felon is

A. Thumb B. Index finger
C. Middle finger D. Ring finger

385. Most common cause of monoarthritis in children in India is

A. Septic arthritis B. Osteoarthritis
C. Tuberculous arthritis D. RA

386. X-ray knee of the patient with following image shows:

A. Ewing's sarcoma B. Osteosarcoma
C. Callus D. Broadie's abscess

387. A 18-year old male presents with a draining sinus on his left leg with pus discharge and discharge of bony pieces since 3 months. The diagnosis is:

A. Chronic osteomyelitis
B. Ewing's sarcoma
C. Osteoid osteoma
D. Cellulitis

388. Total duration of antibiotics in acute osteomyelitis is:

A. 4 weeks B. 2 weeks
C. 6 weeks D. 8 weeks.

389. The diagnosis for the following image in a 15 year old girl with sinus in the thigh and old healed scar?

A. Ewings sarcoma B. Chr. Osteomyelitis
C. Osteosarcoma D. Broadie's abscess

390. The diagnosis for the following image (MRI) in a 15 year old girl with sinus in the thigh and old healed scar?

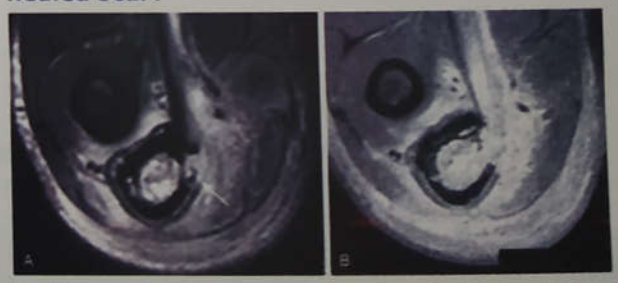

A. Ewings sarcoma B. Chr. Osteomyelitis
C. Osteosarcoma D. Broadie's abscess

391. All are about chronic osteomyelitis except:

A. Reactive new bone formation
B. Cloaca is an opening in involucrum
C. Sequestrum is dead bone
D. Sequestrum is heavy bone

376. a	377. a	378. a	379. b	380. a	381. d	382. a	383. b	384. a	385. c	386. d
387. a	388. c	389. b	390. b	391. d						

392. Chronic persistent neutrophilic discharged is seen in:

A. Chronic osteomyelitis
B. Acute osteomyelitis
C. Septic arthritis
D. None

393. Sequestrum is best defined as:

A. A piece of dead bone
B. A piece of bone with poor vascularity
C. A piece of dead bone surrounded by infected tissue
D. None

394. Chronic osteomyelitis is diagnosed mainly by:

A. Sequestrum
B. Bone fracture
C. Deformity
D. Brodies'sabcess

395. Which of the following is NOT TRUE regarding tubercular osteomyelitis:

A. It is a secondary TB.
B. Periosteal reaction is seen
C. Sequestration is uncommon
D. Inflammation is minimum

396. True about HIV, osteomyelitis is all except:

A. Necrosis absent
B. often bilateral
C. periosteal new bone formation
D. most common cause is staphylococcus aureus

397. Installation treatment in osteomyelitis is:

A. Continuous suction + continuous drainage
B. Intermittent suction + continues drainage
C. Continuous suction + intermittent drainage
D. Intermittent suction + intermittent drainage

398. The ideal treatment for acute osteomyelitis of long bones is:

A. Antibiotics only
B. Drilling of bone
C. Decompression
D. Antibiotics and if indicated decompression

399. Tom smith arthritis is:

A Tuberculosis involvement of hip joint
B Tuberculosis involvement of knee joint
C Syphilitic arthritis of hip joint
D Septic arthritis of hip joint infants

400. In case of suspected septic arthritis, best way to confirm the diagnosis is by:

A. Aspiration of joint
B. CT scan (computerized tomography)
C. MRI scan (magnetic resonance imaging)
D. Blood investigations

401. Which of the following is an orthopaedic emergency

A. Intra-articular fracture
B. Septic arthritis
C. Fracture lateral condyle humours
D. Fracture neck femur

402. Most common joint involved in septic arthritis.

A. Knee
B. Flip
C. Shoulder
D. Elbow

403. Identify the disease?

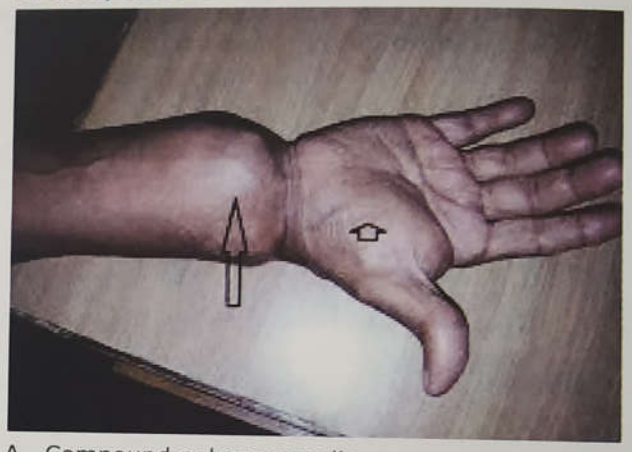

A. Compound palmar ganglion
B. Malunited fracture distal radius
C. Madura foot
D. Madelung deformity.

404. Bony ankylosis result from

A. Pyogenic arthritis
B. Tuberculosis arthritis
C. Osteoarthritis
D. Rheumatic arthritis

405. A patient with swollen foot, pus discharge, multiple sinuses. KOH smear shares filamentous Structures. Diagnosis is

A. Osteomyelitis
B. Madura Mycosis
C. Anthrax
D. Tetanus unilateral

392. a	393. c	394. a	395. b	396. a	397. a	398. d	399. d	400. a	401. b	402. a
403. a	404. a	405. b								

376. A. Salmonella

S. aureus is the M/c cause of osteomyelitis in normal population, but in sickle cell patients, salmonella is the M/C cause.

377. A. Tenosynovitis

Disproportionate pain on passive extension is the most important component of kanavel sign.

378. A. Staphylococcus aureus

Most common in all age groups	S. aureus
Sickle cell anaemia	Salmonella
I/V drug addicts	Pseudomonas
HIV, Immunocompromised	S. aureus
In open fractures and post traumatic cases	S. aureus
Post surgical cases	S. aureus
Sexually active	Neiserria gonorhea
Animal bite	Pasteurella
Human bite	Eikenella
Diabetic ulcers	Anaerobes
Healthy infant of 2-4 weeks	S.aureus
Premature infant under treatment in N-ICU	S. aureus/ Gram –ve
Puncture wound of foot	Pseudomonas

379 B. Loss of soft tissue planes

1) Xray-

- Normal in < 24hours
- 1st change on xray is loss of soft tissue planes/ haziness due to increased blood flow seen after 48 hours.
- 1st bony change is periosteal reaction and seen after 7-10 days.

380. A. Knee

Knee is the M/C joint involved in septic arthritis followed by hip.

381. D. Increased hip mobility & instability

Tom Smith arthritis is the fulminating septic arthritis of hip joint & destroys the joint l/t increased mobility and shortening.

382. A. TB Hip

In HIV patients TB is more common then AVN. When arthritis sets in, the deformity is generally FADIR (Flexion, adduction & IR). But, in initial stage, deformity in TB hip is FABER (as in any infective pathology of hip) while in AVN is limitation of abduction and IR.

383. B. Mandible

- Actinomycosis- m/c involves orocervicofacial region

Overall mc site is mandible.

384. A. Thumb

- The most common site being thumb followed by the index finger.

385. C. Tuberculous arthritis

Tuberculosis is the M/C cause of monoarthritis in children in India. Whereas, RA is mostly polyarticular and OA is rare in pediatric population.

386. D. Broadie's abscess

Xray is classical of Broadie's abscess, with lytic cavity in epi-metaphyseal with sclerotic margin. Whereas, ewing is a diaphyseal tumour, & osteosarcoma presents with sunray appearance.

387. A. Chronic osteomyelitis.

The history given in the que. are "the diagnostic" features of Chronic o'myelitis.

388. C. 6 weeks

Antibiotics are given for 6 weeks normally, 2 weeks I/V and 4 weeks oral.

389. B. Chronic osteomyelitis.

Xray is classical of chronic osteomyelitis, showing sequestrum, cloaca with the presenting clinical picture. Ewings is a D/D of acute osteomyelitis. Osteosarcoma does not present with such xray picture.

390. B. Chronic osteomyelitis.

In Chronic O'myelitis MRI may reveal a well-defined rim of high signal intensity surrounding the focus of active disease (Penumbra/ Rim sign)

391. D. Sequestrum is heavy bone

Sequestrum is a (dead) lighter bone which floats on water.

392. A. Chronic osteomyelitis

It is classical of Chronic osteomyelitis not seen in acute / septic arthritis.

393. C. A piece of dead bone surrounded by infected tissue.

Sequestrum is defined as a piece of dead bone surrounded by infected tissue. Both option A) & C) includes dead bone, but option C) is complete definition of sequestrum, thus the best ans. Of choice.

394. A. Sequestrum

Pathognomic of chronic osteomyelitis.

395. B. Periosteal reaction is seen

Periosteal reaction is usually not seen in tubercrular osteomyelitis

396. A. Necrosis absent

After septic arthritis the next m/c musculo skeletal infection in HIV patients is osteomyelitis.The disease in HIV patients also is mostly caused by Staph aureus, although in one third cases the infection is polymicrobial. The pathology is absolutely similar with necrosis of bone and a periosteal reaction. However, involvement may at times be bilateral.the bone m/c involved is tibia.

397. A' Continuous suction + continuous drainage.

Instillation suction technique- may be used after debridement where 2 pipes are used for antibiotic irrigation and other for suction. Continuous suction / drainage is the principle.

398. D. Antibiotics and if indicated decompression.

Decompression is done by making drill holes in the bone, to relieve the intra medullary pressure. If pus escapes out of holes, then a window is created for continuous drainage of the pus.

399. D. septic arthritis of hip joint infants.

Its a fulminant septic arthritis of hip, not tubercular / syphilitic.

400. A. Aspiration of joint

Invasive investigation, although the best, but should never be the 1st investigative modality.

401. B. Septic arthritis.

Septic arthritis is an orthopaedic emergency, while other intra-articular fracture is an urgency.

402. A. Knee.

Knee is the M/C joint involved in septic arthritis followed by hip.

403. A. compound palmar ganglion

Its a classical picture of compound palmar ganglion, with two swellings across the wrist.

404. A. Pyogenic arthritis.

Pyogenic arthritis results in bony ankylosis whereas, tubercular leads to fibrous ankylosis, until and unless complicated by superadded pyogenic infection, where it can result into bony ankylosis.

405. B. Madura Mycosis

Swollen foot, KOH smear positive points to Madura foot.

Tuberculosis — Questions

406. Most common site of TB:
A. Spine
B. Knee
C. Hip
D. Shoulder

407. A patient with tuberculosis of spine first neurological sign is:
A. Motor loss
B. Sensory loss
C. Increased deep tendon reflexes
D. Bladder involvement

408. The earliest radiological sign in pott's disease is:
A. Erosion of vertebral bodies
B. Collapse and destruction of vertebral
C. Narrowing of intervertebral disc space
D. Paraspinal soft tissue shadow

409. Identify the maneuvere

A. Treatment for deformity correction
B. Reverse hanging
C. Strangulation
D. Lynching

410. Investigation of choice for spinal tuberculosis usually is:
A. X-Ray
B. CT-Scan
C. Open biopsy
D. MRI

411. Identify the procedure?
A. Anterolateral decompression
B. Postero lateral decompression
C. Surgery for scoliosis
D. Surgery for PIVD

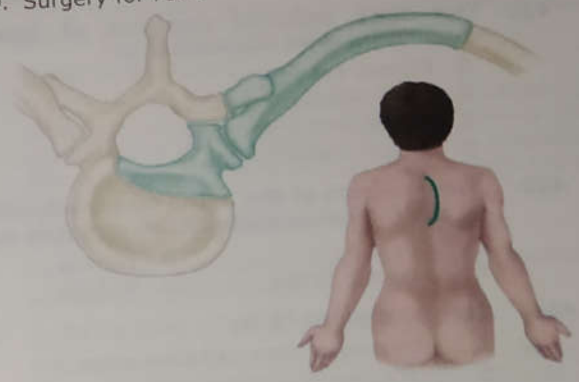

412. Poor prognosis indicator of pott's paraplegia
A. Early onset
B. Active disease
C. Healed disease
D. Wet lesion

413. All are true about spinal tuberculosis expect:
A. Back pain earliest symptom
B. Dorsolumbar spine commonest site
C. Exaggerated lumbar lordosis
D. Secondary to lung infection

414. TB hand:
A. Spina ventosa
B. Caries sicca
C. Pott's Disease
D. None

415. Antero lateral decompression is done for:
A. Sacral
B. Cervical
C. Dorsolumbar
D. Lumbosacral

416. Tuberculosis with polyarthritis is called as:
A. Poncet's disease
B. Barton's disease
C. Von Gierke disease
D. Gordon's disease

417. Indication of steroids in Pott's spine:
A. Pain
B. Deformity
C. Meningitis
D. Fever

418. Hong Kong's operation is done for?
A. Tuberculosis
B. Leprosy
C. Septic arthritis
D. Osteomyelities

419. Tuberculosis of spine best diagnostic modalit is:
A. Clinical
B. X-ray
C. MRI
D. CT guided biopsy

420. Tuberculosis in Bone is due to?
A. Paucibacillary and hematogenous
B. Multibacillary and hematogenous
C. Paucibacillary and lymphatic
D. Multibacillary and lymphatic

406. a	407. c	408. c	409. a	410. d	411. a	412. c	413. c	414. a	415. c	416.
417. c	418. a	419. d	420. a							

421. A 35-year- old lady with chronic backache. On X-ray she had a D12 collapse. But inter vertebral disk spine maintained. All are possible except:

A. Multiple myeloma
B. Osteoporosis
C. Metastasis
D. Tuberculosis

422. The most common sequelae of tuberculous spondylitis is an adolescent is:

A. Fibrous ankylosis
B. Bony- ankylosis
C. Pathological dislocation
D. Chronic osteomyelitis

423. Tuberculosis of the spine commonly affects all of the following parts of the vertebra except:

A. Body
B. Lamina
C. spinous process
D. Pedicle

424. The 1st sign of TB is:

A. Narrowing of inter vertebral space
B. Rarefaction of vertebral bodies
C. Destruction of laminae
D. Fusion of spinous processes

425. The most common type of spinal tuberculosis is?

A. Anterior
B. Posterior
C. Central
D. Paradiscal

426. The most common cause of kyphosis in a male is?

A. Congenital
B. Tuberculosis
C. Trauma
D. Secondaries

427. Surgical treatment in pott's spine is indicated if there is?

A. Progressive loss of function in spite of medical treatment
B. Pain
C. There is no improvement in fever in 3 months of treatment
D. Patient who is an adult or middle age

428. In bony ankylosis, there is?

A. Painless, no movement
B. Painful complete movement
C. Painless complete movement
D. Painful incomplete movement

429. A 25 Y/M complaints of pain in lower back region for three months. Has history of slipping of bathroom slippers. Mild weakness of both lower limbs but can walk without support. There is 30% sensory loss and has bladder symptoms. D12-L1 is tender. X-ray shows paradiscal destruction of vertebrae and MRI shows destruction with indentation of thecal sac. Management is?

A. Wait and Watch
B. Domicilary ATT
C. Admit and ATT
D. ATT and Decompression

430. Anterolateral decompression (ALD) and anterior decompression (AD) for Pott's spine all are true except?

A. ALD and AD results are the same
B. ALD position of patient is right lateral
C. ALD laminectomy is always a part
D. ALD part of ribs is removed and spinal nerves exposed

431. Wandering acetabulum is seen in

A. Fracture acetabulum
B. CDH
C. Dislocation of femur
D. TB hip

421. d	422. b	423. c	424. a	425. d	426. b	427. a	428. a	429. d	430. c	431. d

406. A. Spine

- Amongst skeletal system, spine is the most common site of involvement, followed by the hip, knee, foot, elbow, hand and shoulder in order of frequency.

407. C. Increased deep tendon reflexes

1st neurological sign is extensor plantar or clonus.

408. C. Narrowing of intervertebral disc space

- Osteopaenia f/b loss of definition of paradiscal margins and disc space reduction are the earliest findings, seen in the commoner paradiscal type of tuberculosis.

409. A. Treatment for deformity correction

In ancient times this manuevere was done for deformity correction in pott's spine.

410. D. MRI

MRI – is the best investigation, provides earliest diagnosis and is the IOC. Can also evaluate the status of spinal cord. But the gold standard for diagnosis is CT guided biopsy.

411. A. Anterolateral decompression

Image shows the area of resection in Anterolateral decompression.

412. C. Healed Disease

All other mentioned options are good prognostic indicators.

413. C. Exaggerated lumber lordosis

Spine is the M/C site of skeletal TB and mostly is due to pulmonary tuberculosis. DL spine is the M/C site and back pain being the earliest symptom.

414. A. Spina ventosa

Caries sicca – TB of shoulder, Pott's disease – TB outside of lung.

415 C. Dorosolumbar

DL spine is the M/c site of Pott's spine and surgery done is ALD.

416. A. Poncets disease

Barton's disease is bartonellosis (bacteria), Von Gierkes is metabolic disease and Gordon's is a type of arthrogryposes.

417 C. Meningitis

Meningitis is one of the indication of steroid in potts spine, to reduce inflammation and prevent brain damage.

418. A. Tuberculosis

Hong Kong procedure – Radical anterior decompression and spinal fusion.

419 D. CT guided biopsy

CT guided biopsy is the gold standard modality for diagnosis of Pott's spine.

420. A. Paucibacillary and hematogenous

- Infection is paucibacillary and is mostly secondary to lung infection (50-75% patients have concomitant pulmonary lesion).

421. D. Tuberculosis

In TB spine, IVD space is compromised and is also one of the earliest xray feature.

422. B. Bony-ankylosis

Ankylosis- in TB arthritis generally the outcome is fibrous ankylosis, but if superadded infection is also present than the outcome may be bony ankylosis. But in spinal TB the outcome is often bony rather than fibrous.

423. C. spinous process

Facet joints f/b spinous process is least commonly involved in Pott's spine.

424. A. Narrowing of inter vertebral space-

The earliest radiological feature of spinal tuberculosis is reduction of intervertebral disk space and osteoporosis of two adjacent vertebrae sometime with fuzziness of the endplates.

425. D. Paradiscal

Paradiscal is the M/c type & posterior is the least common variety.

426. B. Tuberculosis

Tuberculosis is the most common cause of kyphosis in males. The deformity being maximum in dorsal spine > lumber spine> cervical spine.

427. A. Progressive loss of function in spite of medical treatment

Indication for surgery-

- Indicated in cases when there is deterioration in clinical / neural status when patient is on ATT or when there is no improvement after conservative trial for 3-4 weeks.
- Paravertebral abscess leading to dyspnoea/ dysphagia (aspiration of abscess is indicated). Abscess as such is not an indication for surgery.
- Grade 4 paraplegia.

428. A. Painless, No movement

Bony ankylosis is painless with no movement, whereas fibrous is painful.

429. D. ATT and Decompression as bladder symptoms are present.

Indications of surgery in any disease of spine.

- Deterioration in neural or clinical status on treatment.
- No improvement in neural or clinical status after conservative trial of 3-4 weeks or.
- Bowel bladder involvement.

430. C. ALD laminectomy is always a part

Posterior structures like lamina are never removed because disease destroys anteriorly and if surgeon destroys posteriorly then there will be instability.

431. D. TB hip

TB hip is classified in 7 types and wandering acetabulum is one such type. As femur head is making a false joint in ilium, it is k/a wandering acetabulum, as shown in xray.

Osteochondritis — Questions

432. Most common site of Osteochondritis dissecans?

A. Lateral part of the medial femoral condyle
B. Medial part of the medial femoral condyle
C. Lateral part of the lateral femoral condyle
D. Medial part of the lateral femoral condyle

433. A-30- year –old HIV positive male who is on antiretroviral therapy (protease inhibitors) has pain in the right hip joint for 2 month. He has difficulty in abduction and internal rotation. Which of the following is most likely diagnosis?

A. Septic arthritis
B. Osteochondritis
C. Avascular necrosis
D. Tubercular arthritis

434. Potential causes of AVN include?

A. Prolonged intake of steroids
B. Sickle cell anemia
C. Posterior dislocation hip
D. All

435. A patient with the history of trauma, a year back, comes with complain of wrist pain and the following xray, diagnosis is:

A. Kohlers disease
B. Keinbock's disease
C. AVN of scaphoid
D. Colles fracture.

436. Most common cause of AVN of the hip is?

A. Idiopathic
B. Alcoholism
C. Caissons disease
D. Fracture neck of femur (Post –Traumatic).

437. Which of the following part of the bone is not prone for AVN?

A. Proximal scaphoid
B. Body of talus
C. Femoral neck
D. Femoral head

438. Kienbock's disease is Osteochondritis of?

A. Scaphoid
B. Lunate
C. Calcaneum
D. Tibial tuberosity

439. Avascular necrosis investigation of choice?

A. X-ray
B. CT scan
C. Bone scan
D. MRI

440. Avascular necrosis affects which part of femoral head?

A. Anteromedial
B. Anterolateral
C. Posteromedial
D. Posterolateral

441. Avascular necrosis is seen at proximal pole of scaphoid because?

A. Blood supply enters proximal pole
B. Blood supply enters through the waist
C. Blood supply enters though the distal pole
D. Proximal pole is intra-articular

442. Osteochondritis in Osgood Schlatter disease affect which bone?

A. Capitulum's bone
B. Metacarpal
C. Navicular
D. Tibial tuberosity

443. A 50- year-old man sustained posterior dislocation of left hip in an accident. Dislocation was reduced after 3 days. He started complaining of pain left after 6 months. X- ray of the pelvis was normal. The most relevant investigation at the stage will be?

A. CRP Levels in blood
B. Ultrasonography of hip
C. Arthrography of hip
D. MRI of hip

444. A woman of 45, a known cause of pemphigus vulgaris on a regular treatment with controlled primary disease presented with pain in the right hip and knee. Examination revealed no limb length discrepancy but the patient has tenderness in the scarpa's triangle and limitation of abduction and internal rotation of the right hip joint as compared to the other side. The most probable diagnosis is?

A. Stress fracture of neck of femur
B. Avascular necrosis of femoral head
C. Perthes disease
D. Transient synovitis of hip

445. Scheuerman's disease occurs in?

A. Adults
B. Elderly
C. Infants
D. Adolescents

432. a	433. c	434. d	435. c	436. a	437. c	438. b	439. d	440. b	441. c	442. d
443. d	444. b	445. d								

446. An adolescent male with complain of pain in knee for last few months after playing, with no history of trauma comes with this xray, diagnosis is:

A. Osteochondritis dessicans of femur
B. Osteochondritis dessicans of patella
C. Osgood Schlatter disease
D. Tibial tuberosity fracture

447. In elbow, Osteonecrosis usually involves?

A. Olecranon
B. Trochlea
C. Radius head
D. Capitulum

448. Osteochondritis is not seen in- disease?

A. Slipped capital femoral epiphysis
B. Panner's disease
C. Calve's disease
D. Kohler's disease

449. Microfracture technique is carried out for?

A. Non- union
B. Osteochondral defects
C. Tumors
D. Osteonecrosis

450. A patient is using oral steroids for a period of 5+ years and patient complaints of pain in the hip regions. Which one of the following is a diagnostic modality for confirmation of diagnosis?

A. Plain X-ray
B. CT scan
C. MRI
D. Isotope Bone scan

446. c	447. d	448. a	449. b	450. c

432. A. Lateral part of the medial femoral condyle.

Lateral part of the medial femoral condyle is the M/C site of Osteochondritis dissecans.

433. C. Avascular necrosis-

HIV/Protease inhibitors with hip pain, restricted abduction & IR – diagnosis – AVN.

434. D. ALL

All can cause AVN of femur head.

435. C. AVN of scaphoid.

Fracture through the waist of scaphoid, with sclerosis of proximal part of scaphoid with normal distal part – diagnosis post-traumatic AVN of scaphoid.

436. A. Idiopathic.

All options are the causes of AVN head femur, but idiopathic is the M/C cause.

437. C. Femoral neck

Fracture neck of femur leads to AVN of head femur not vice-versa.

438. B. Lunate.

Kohler	Navicular
Keinbock	Lunate
Preiser	Scaphoid
Osgood Schlatter	Tibial tuberosity
Hagelund	Calcaneus

439 D. MRI

MRI is the IOC for AVN and it can detect AVN at the earliest. But once AVN is visible on Xray (i.e late cases), than MRI has no added advantage.

440. B. Anterolateral

Anterolateral/ superolateral part of head femur is affected most by AVN.

441. C. Blood supply enters though the distal pole

Blood supply to scaphoid enters through distal pole, supplying it distally and vessels turn in retrograde direction to supply the proximal bone, as end arteries.

442. D. Tibial tuberosity.

Panner – capitulum, Metacarpal – Dietrich, Navicular – kohler.

443. D. MRI of hip

- Diagnosis here is of AVN and it is best/earliest picked by MRI.

444. B. Avascular necrosis of femoral head

- Limitation of abduction and internal rotation in a patient with a disease where he might be taking steroids, makes the diagnosis of AVN of femoral head. Always look in the question, if any disease is mentioned, examiner is indirectly giving a clue of long term steroid intake.

445. D. Adolescents.

Scheuerman's disease is the osteochondritis of ring epiphysis of vertebrae, occuring in adolescent population.

446. C.' Osgood Schlatter disease

Osgood Schlatter disease- osteochondritis of tibial tuberosity, appears as fragmentation on xray.

447. D. Capitulum.

Capitulum is the M/C site of osteochondritis in elbow, and is k/a Panner's disease.

448. A. Slipped capital femoral epiphysis.

Panner – capitulum, Kohler – navicular, calve's – central bony nucleus of vertebrae. SCFE is not an osteochondritis, but it can l/t AVN of head of femur.

449. B. Osteochondral defects.

Microfracture technique is carried out for Osteochondral defects, so that pleuripotent cells emerge from microfracture sites and helps in healing of chondral defect.

450. C. MRI.

- Whenever steroid /any disease where long term steroid intake may be a possibility, is mentioned in question, think of AVN.

451. The following is false about achondroplasia
A. Due to gene mutation
B. Mental retardation
C. AD
D. Shortening of limbs present

452. A 9-year-old child has high arched palate with shoulders meeting in front of his chest. Diagnosis is?
A. Cleidocranial dysostosis
B. Erb's palsy
C. Chondro-osteodystrophy
D. Cortical hyperostosis

453. Phocomelia is characterized by
A. Absence of short bones
B. Complete absence of extremities
C. Defects of long bones of limb
D. Partial absence of extremities

454. Nail patella syndrome is characterized by
A. Iliac horn
B. Sacral horn
C. Knee deformity
D. Dislocation of knee.

455. The characteristics of Morquio's disease include all except
A. Spinal kyphosis
B. Subnormal intelligence
C. Excessive excretion of keratin-sulphate in urine
D. Dwarfism

456. Ring shaped epiphyses is seen in:
A. Osteogenesis imperfecta
B. Morquio's syndrome
C. Zellweger syndrome
D. Multiple epiphyseal dysplasia

457. Prenatal determination of osteogenesis imperfecta is done by:
A. Acid phosphatase
B. Alkaline phosphatase
C. Abnormal Pro- a chain
D. FGF3 mutation

458. Not true about osteogenesis imperfecta:
A. Impaired healing of fracture
B. Deafness
C. Laxity of joints
D. Fragile fracture

459. Wormian bones are seen in:
A. Osteogenesis imperfecta
B. Scheuermann's disease
C. Paget's disease
D. Osteoclastoma

460. Osteopetrosis, false is:
A. Low levels of serum calcium
B. Raised levels of alkaline phosphatase
C. Low levels of PTH
D. Low levels of serum phosphate

461. A 3-year-old male presented with progressive anemia, hepatosplenomegaly and osteomyelitis of jaw with pathological fracture. X-Ray shows chalky white deposits in bone. Probable diagnosis is
A. Alkaptonuria
B. Osteopetrosis
C. Myositis ossificans progerssiva
D. Osteopoikilosis

462. Dripping candle wax appearance on X-ray of spine is seen in
A. Osteopetrosis
B. Metastasis
C. TB spine
D. Melorheostosis

463. Caffey's disease is?
A. Renal osteodystrophy
B. Infantile cortical hyperostosis
C. Osteomyelitis of jaw in children
D. Chronic osteomyelitis in children

451. b	452. a	453. c	454. a	455. b	456. a	457. c	458. a	459. a	460. c	461. b
462. d	463. b									

451. B. Mental retardation

These children have normal intelligence & is aka circus dwarf.

452. A. Cleidocranial dysostosis

In cleido-cranial dystosis clavicles may be underdeveloped or absent. M/C defect is loss of lateral 1/3rd clavicle>loss of middle third clavicle. Due to absence of clavicle shoulders look droopy, chest appears narrow & when B/L loss is there, both shoulders can touch each other in front of the chest.

453. C. Defects of long bones of limb

- Amelia- complete absence of limb.
- Phocomelia (meaning seal like limbs) is a birth defect wherein the proximal bones of the limbs are shortened, such that the hands and the feet are located very close to the trunk.
- Amelia totalis- complete absence of all four limbs.
- Acromelia is due to the shortening of foot and hand bones.

454. A. Iliac horn

- Nail-Patella Syndrome (Onycho-osteo-dysplasia) - dystrophy of the nail (M/C thumb) and hypoplastic or absent patella, hypoplastic lateral femoral condyle l/t recurrent patella dislocation.
- X-ray features: Hypoplastic or absent patella, bilateral posterior iliac horns (Fong's prongs) and prominent anterior iliac spine are characteristic features.

455. B. Subnormal intelligence

Achondroplasics have large head with prominent mandibles, small maxillae and depressed nasal bridge. However, these children have normal intelligence (**circus dwarf**).

456. A. Osteogenesis imperfecta

457. C. Abnormal Pro- a chain

Prenatal- PCR can be conducted on chorionic villi biopsy at 8-12 weeks, to detect the abnormal pro-alpha chain.

458. A. Impaired healing of fracture

Bone remodeling is defective; fracture healing, however is normal, but fractures tend to heal with abundant callus, although the callus is of poor quality.

459. A. Osteogenesis imperfecta

Causes of wormian bones- **CHORD**

- Cleidocranial dystosis.
- Hypothyroidism/hypophosphatasia
- Osteogenesis imperfect.
- Rickets.
- Down's syndrome.

460. C. low levels of PTH

Decreased bone resorption l/t low Ca and high ALP -> high PTH -> low Phosphate.

461. B. Osteopetrosis

Pancytopenia due to obliteration of marrow cavity by bony overgrowth (abnormal bleeding, anemia, infections and failure to thrive). Due to pancytopenia, there is extramedullary haematopoiesis (hepatospleenomegaly). Bone pain and pathological fractures(fragile brittle bone) are common.

462. D. Melorheostosis

- Melorheostosis/ Leri's Disease (Candle Bone Disease) -ray picture is characteristic (Fig. 14.8) showing asymmetrical, irregular cortical sclerosis giving the appearance of wax dripping down the side of a candle appearance.

463. B. Infantile cortical hyperostosis.

It is a self-limiting inflammatory disease of unknown etiology, in infants (< 6 months old), characterized by intense diaphyseal periostitis and hyperostosis (thickening of cortex of bone often leading to doubling of width of bone), occurrence of soft tissue nodules and growth abnormalities.

464. Which of the following statement is incorrect regarding Osteoporosis?

A. i/v Parathormone is useful in severe osteoporosis
B. T-score is less than 2.5
C. Bisphosphonates are the mainstay of treatment
D. Calcitonin is useful in acute pain
- It is given sub-cutaneously not i/v.

465. A 60 years old female with long term steroid intake, presents with backache. X- ray spine done as shown below, next investigation to be done is?

A. DEXA
B. PTH
C. Calcium
D. Calcitriol

466. Z score measures the bone mineral density compared to?

A. Age, race and sex matched individuals
B. Race and sex matched individuals
C. Sex matched individuals
D. None of the above

467. Osteoporosis which of the following is false?

A. Osteoporosis is defined, if t score is less than-1.5
B. Severe osteoporosis PTH is used for treatment
C. Calcitonin decreases the bone pain
D. Bisphosphonates are cornerstone of treatment

468. Which of the following is not a treatment option for osteoporosis?

A. Denosumab
B. Alendronate
C. Vertebroplasty
D. Corticosteroids

469. Rickets in infancy is characterised by all of the following except

A. Wide open fontanelle
B. Bow legs
C. Rachitic rosary
D. Craniotabes

470. Which of the following is used in osteoporosis for decreasing bone resorption and increasing bone formation?

A. Teriparatide
B. Calcitonin
C. Strontium ranelate
D. Bisphosphonate

471. Most common cause of kyphotic deformity?

A. Trauma
B. Osteoporosis
C. Ankylosing spondylitis
D. Rickets

472. A bald child with swollen abdomen, hyperosseous bones has?

A. Hypervitaminosis C
B. Hypervitaminosis D
C. Down's syndrome
D. Tuberous sclerosis

473. The most common manifestation of osteoporosis is?

A. Compression fracture of the spine
B. Asymptomatic, detected incidentally by low serum calcium
C. Bowing of legs
D. Loss of weight

474. A patient of osteoporosis on medication, complained of hip pain. Xray was done. What drug was she taking:

A. Bisphosphonates
B. Strontium Ranelate
C. Calcium
D. Teriparatide

475. The maximum change in bone mineral density in hemiplegic patients after 1 year is seen in

A. Lumbar spine
B. Proximal femur of the paralysed side
C. Distal radius of the paralysed side
D. Humerus of the paralysed side

464. a	465. a	466. a	467. a	468. d	469. b	470. c	471. b	472. b	473. a	474. a
475. d										

476. Blade of grass lesion is seen in

A. Thalassemia
B. Osteoporosis
C. Carcinoma Prostate
D. Paget's disease

477. As per current recommendations which vitamin is required with Vitamin D for treatment of osteoporosis?

A. Vitamin A
B. Vitamin B
C. Vitamin C
D. Vitamin K

478. A 2- year old child with rickets is on calcium supplements and has a foot deformity. The child will be referred to a surgeon for the correction of the deformity when?

A. Serum calcium levels are normal
B. Serum vitamin D levels are normal
C. Growth plate healing becomes normal
D. Serum ALP becomes normal

479. In Rickets all are seen except?

A. Bowing of legs
B. Rachitic rosary
C. Bleeding
D. Craniotabes

480. Which of the drugs cause Osteomalacia?

A. Phenytoin
B. Valproate
C. Carbamazepine
D. Aspirin

481. Looser zone is fracture of?

A. Osteoporosis
B. Osteomalacia
C. Metastasis
D. Scurvy

482. Decreased mineralization of epiphyseal plate in a growing child is seen in?

A. Rickets
B. Osteomalacia
C. Scurvy
D. Osteoporosis

483. Basic pathological defect in rickets is?

A. Decreased Osteoblastic activity
B. Nonfunctional osteoclast
C. Defective osteoclastic resorption of uncalcified osteoid and cartilage
D. Defective proliferation of physis

484. A patients with raised serum alkaline phosphatase and raised parathormone level along with low calcium and low phosphate level is likely to have?

A. Primary hyperparathyroidism
B. Paget's disease
C. Osteoporosis
D. Vitamin D deficiency

485. Primary Hyperparathyroidism is associated with?

A. Increased serum PTH and hypercalcemia
B. Decreased serum PTH and hypercalcemia
C. Increased serum PTH and hypocalcemia
D. Decreased serum PTH and hypocalcemia

486. A 70 year old male, known case of chronic renal failure suffers from a pathological fracture of right femur, the diagnosis is?

A. Primary hyperparathyroidism
B. Secondary hyperparathyroidism
C. Scurvy
D. Vitamin D resistant rickets

487. A 55 years old male having bony pains for last two years presents with the image shown below. Most probable diagnosis is?

A. Multiple myeloma
B. Paget's disease
C. Hyperparathyroidism
D. Eosinophilic granuloma

488. This xray is a feature of?

A. Hyperthyroidism
B. Hyperthyroidism
C. Hypoparathyroidism
D. Hyperparathyroidism

476. d	477. d	478. d	479. c	480. a	481. b	482. a	483. c	484. d	485. a	486. b
487. a	488. d									

489. Short 4th metacarpal is a fracture of?
A. Hyperparathyroidism
B. Hypoparathyroidism
C. Pseudohypoparathyroidism
D. Scleroderma

490. Rugger jersey spine in CRF is due to?
A. Osteomalacia
B. Trauma
C. Hyperparathyroidism
D. Aluminium osteodystrophy

491. A female eating only junk food, pinpoint ecchymoses around follicle. Bleeding into joints and subperiosteal hemorrhages, swollen tongue and gingivitis. What is the defects?
A. Hydroxylation of lysine and proline
B. Carboxylation of clothing factors
C. Deficiency factor VIII
D. Deficiency factor IX

492. Barton's disease is?
A. Scurvy and rickets
B. Scurvy and fracture
C. Rickets and fracture
D. Scurvy and syphilis

493. Metaphyseal fracture is commonly seen in?
A. Osteogenesis imperfecta
B. Scurvy
C. Rickets
D. None

494. What is the diagnostic radiological finding in skeletal fluorosis?
A. Sclerosis of sacroiliac joint
B. Interosseous membrane ossification
C. Osteosclerosis of vertebral body
D. Ossification of ligaments of knee joint

495. All are features of Paget's disease except:
A. Defect in osteoclasts
B. Common in female
C. Can cause deafness
D. Can cause osteosarcoma

496. Pain in Paget's disease is relieved best by:
A. Simple analgesics
B. Narcotic analgesics
C. Radiation
D. Calcitonin

497. A 60- year – old male with bony abnormality at upper tibia associated with sensorineural hearing loss. On laboratory examination serum alkaline Phosphatase levels are (440mU/I) elevated and serum Ca++ and PO are normal. Skeletal survey shows ivory vertebrae and cotton wool spots in X-ray skull. Diagnosis is
A. Fibrous dysplasia
B. Paget's disease
C. Osteosclerotic matastasis
D. Osteoporosis

498. Vitamin D deficiency rickets is confirmed by demonstration of
A. Epiphyseal changes in X-ray
B. Hypocalcaemia and hypophosphatemia
C. Raised serum alkaline phosphatase
D. Healing with physiologic doses of vitamin d3

499. Drug of choice for bisphosphonate resistant osteoporosis
A. Teriparatide
B. Denosumab
C. Anakinra
D. Calcitonin

500. A 55 years old male having bony pains for last two years presents with the image shown below. Most probable diagnosis is?

A. Multiple myeloma
B. Paget's disease
C. Hyperparathyroidism
D. Eosinophilic granuloma

501. Characteristic feature of haemophilia?
A. Haemarthrosis
B. Haematemesis
C. Bleeding varices
D. Haemoptysis

489. c	490. c	491. a	492. a	493. b	494. b	495. b	496. d	497. b	498. d	499. a
500. a	501. a									

464. A. i/v Parathormone is useful in severe osteoporosis

- It is given sub-cutaneously not i/v.

465. A. DEXA

It is clear cut case of severe osteoporosis. Next investigation is DEXA to grade the osteoporosis and start treatment accordingly.

466. A. Age, race and sex matched individuals

T-score: It measures BMD & compares to the reference value (30-year-old of the same sex, ethnicity)

Z-score: It compares BMD with a subject of the same age, sex and race/ethnicity.

467. A. Osteoporosis is defined, if t score is less than-1.5

Osteoporosis—diagnostic criteria	
	BMD T-Score
Normal	< 1 SD below normal
Osteopenia	1–2.5 SD below normal
Osteoporosis	≥ 2.5 SD below normal with no h/o fractures
Severe osteoporosis	≥ 2.5 SD below normal with h/o non-violent fractures

468. D. Corticosteroids

- Steroids is not used in the treatment of osteoporosis, infact its a risk factor for developing osteoporosis.

469. B. Bow legs

- Leg deformities develop only after the child starts walking, i.e after the age of 1 year.

470. C. Strontium ranelate

Teriparatide – stimulate formation, calcitonin / bisphosphonate – inhibit resorption; Strontium ranelate is the only drug which has both the actions.

471. B. Osteoporosis

Osteoporosis is the overall M/C cause of kyphotic deformity, but in children M/C cause is potts spine.

472. B. Hypervitaminosis D

Hypervitaminosis- Vit D has an anti-proliferative effect on cells like keratinocytes, breast cancer cells and prostate cancer cells. It l/t alopecia and Ca mobilisation from bones and metastatic calcification.

473. A. Compression fracture of the spine.

- MC presentation is asymptomatic (S. Ca, Ph, ALP levels are usually normal), but out of the given options 'A' is best suited.

474. A. Bisphosphonates.

This is a case of atypical subrochanteric insufficiency fracture due to bisphosphonates use.

475. D. Humerus of the paralysed side

In hemiplegics maximum drop in bone mineral density occurs in non weight bearing bones of upper limb (maximum in humerus) on the side of hemiplegia.

476. D. Paget's disease

Blade of grass appearance: It is "V" shaped radiolucency seen in the diaphysis of long bones in Paget's disease.

477. D. Vitamin K

Vitamin K deficiency decreases bone mineral density and increases the risk of fractures. Vitamin K along with vitamin D is increasingly being given to prevent and treat osteoporosis.

478. D. Serum ALP becomes normal

Resolution of skeletal deformities occurs completely with treatment with vitamin D and calcium. If the deformity persists even after radiological healing (the best way to predict healing) in rickets, surgery (i.e. corrective osteotomy) to correct that deformity can be done. However, surgery should be done only after the levels of ALP are brought to normal as when ALP is raised, bone is soft and not in a state to hold the fixation implant.

479. C. Bleeding

Bleeding is not a manisfestation of rickets as such.

480. A. Phenytoin

Patients with phenytoin has to be monitored for developing osteomalacia.

481. B. Osteomalacia.

Conditions with Looser's zones:

- Osteomalacia (characteristic)
- Renal osteodystrophy
- Fibrous dysplasia
- Hyperthyroidism
- Paget's disease of bone
- X-linked hypophosphatemia
- Osteogenesis imperfecta

482. A. Rickets

Rickets is a disorder of defective mineralization of the growing skeleton (before epiphyseal closure), the pediatric counterpart of osteomalacia.

483. C. Defective osteoclastic resorption of uncalcified osteoid and cartilage.

The prime pathology in rickets is inadequate mineralization or calcification of physis (growth plates) in growing bones due to deficiency of vitamin D, but osteoid matrix is secreted at a normal rate l/t increased osteoid maturation time(i.e mineralisation).

484. D. Vitamin D deficiency

- In osteoporosis all there blood parameters generally remains normal.

485. A. Increased serum PTH and hypercalcemia.

Primary hyperparathyroidism will lead to increased PTH which in turn will l/t hypercalcemia

486. B. Secondary hyperparathyroidism

CRF leads to secondary hyperparathyroidism.

487. A. multiple myeloma

It is diagnosed in adults over 40 years of age (median age at diagnosis 65 years). Multiple myeloma & metastatic carcinoma are always considered in patients >40 years age with new bone tumour. The most common presentation of MM is generalized bone pain in an elderly patient. Punched out lesions without a reactive zone/sclerotic zone with a sharp zone of transition to normal bone, are found throughout the skeleton

488. D. Hyperparathyroidism

- Subperiosteal resorption of the phalanges is diagnostic (commonly seen on radial sides of middle phalanges) of hyperparathyroidism.

489. C. Pseudohypoparathyroidism

It is seen associated with Turner Syndrome, Albright's hereditary osteodystrophy, pseudohypoparathyroidism, pseudopseudohypoparathyroidism, sickle cell disease, hereditary multiple exostosis and homocystinuria

490. C. Hyperparathyroidism

It refers to appearance of horizontal striped vertebrae seen as a result of alternate bands of bone loss and osteosclerosis in patients with renal osteodystrophy l/t secondary hyperparathyroidism.

491. A. Hydroxylation of lysine and proline

Diagnosis is – Scurvy.

492. A. Scurvy and rickets

Barton's disease: It includes features of both rickets and scurvy.

493. B. Scurvy

Scurvy is a metaphyseal disease with all the Xray signs seen at the metaphysis.

494. B. Interosseous membrane ossification.

Interosseous membrane ossification is the diagnostic finding of fluorosis.

495. B. Common in Female

Pagets disease involves male >> female.

496. D. Calcitonin

Calcitonin is used for acute relief of pain(temporary effect) and is the DOC for pain relief. Otherwise, overall DOC for Paget's disease is Bisphosphonates. etidronate was used first, risedronate is preferred now.

497. B. Paget's disease

The clinical feature mentioned is diagnostic of Paget's disease. In osteoporosis, ALP level is almost normal.

498. D. Healing with physiologic doses of vitamin d3

- Healing with Vit D administration is the best way to diagnose rickets due to vitamin D deficiency.

499. A. Teriparatide

Teriparatide is the DOC for bisphosphonate resistant osteoporosis.

500. A. multiple myeloma

It is diagnosed in adults over 40 years of age (median age at diagnosis 65 years). Multiple myeloma & metastatic carcinoma are always considered in patients >40 years age with new bone tumour. The most common presentation of MM is generalized bone pain in an elderly patient. Punched out lesions without a reactive zone/sclerotic zone with a sharp zone of transition to normal bone, are found throughout the skeleton

501. A. haemarthrosis

Haemarthrosis is the characteristic feature of haemophilia, knee joint being the most common.

502. Epiphysis involved in which bone tumor:

A. Osteosarcoma
B. Multiple myeloma
C. Giant cell tumor
D. Ewing's sarcoma

503. GCT is:

A. Epiphyseal
B. Epiphyseometaphyseal
C. Metaphyseal
D. Metaphyseodiaphyseal

504. Most common tumor of hand:

A. Enchondroma
B. Squamous cell carcinoma
C. Chondroblastoma
D. Melanoma

505. Which of the following is wrongly matched?

A. Osteosarcoma- Sunray appearance
B. Chondroblastoma – Soap bubble appearance
C. Ewing's sarcoma – Onion peel appearance
D. Secondaries of spine – Winking owl sign

506. Which of the following childhood tumors most frequently metastasizes to bone:

A. Neuroblastoma
B. Ganglioneuroma
C. Wilms' tumor
D. Ewing's Sarcoma

507. All of the following tumor are benign tumor except:

A. Chondroma
B. Chordoma
C. Osteochondroma
D. Enchondroma

508. According to a newer hypothesis Ewing's sarcoma arises from:

A. Epiphysis
B. Diaphysis
C. Medullary cavity
D. Cortex

509. X-ray upper end humerus, diagnosis is:

A. Giant cell tumor
B. Simple bone cyst
C. Aneurysmal bone cyst
D. Osteosarcoma

510. All are true about aneurysmal bone cyst except:

A. Eccentric
B. Expansile and lytic
C. Treated by simple curettage
D. Metaphysis of long bones

511. Fallen fragment sign is a feature of:

A. Simple bone cyst
B. Aneurysmal bone cyst
C. Giant cell tumor
D. Fibrous dysplasia

512. A classical expansile lytic lesion in the transverse process of a vertebra is seen in:

A. Osteosarcoma
B. Aneurysmal bone cyst
C. Osteoblastoma
D. Metastasis

513. About Giant cell tumor, all are true except:

A. Commonly presents in the 20-40 years age group
B. Matrix consists of proliferating mononuclear cells
C. Osteoclast gaint cells constitute the proliferative component of the tumor
D. It is a benign tumor which may have lung metastasis.

514. The most likely diagnosis for the tumor at upper end of tibia is:

A. GCT
B. UBC
C. ABC
D. CB

515. GCT malignant component is:

A. Giant cells
B. Mononuclear cells
C. Both
D. None

516. Which of the following is variant of giant cell tumor:

A. Ossifying fibroma
B. Non- Ossifying fibroma
C. Osteogenic sarcoma
D. Chondroblastoma

502. c	503. b	504. b	505. b	506. a	507. b	508. c	509. c	510. c	511. a	512. b
513. c	514. a	515. b	516. b							

517. The Differential diagnosis of lesion, histologically resembling giant cell tumor in the small bones of the hands or feet, includes all of the following except:

A. Aneursymal bone cyst
B. Fibrosarcoma
C. Osteosarcoma
D. Hyperparathyroidism

518. Soap bubble appearance at lower end of radius, the treatment of choice is:

A. Local excision
B. Excision and bone grafting
C. Amputation
D. Radiotherapy

519. Most common benign tumor of the bone is:

A. Giant cell tumor
B. Simple bone cyst
C. Osteochondrorna
D. Enchondroma

520. Factors indicating malignant degeneration in Osteochondroma

A. Size
B. Pain
C. Weight loss
D. Thickness of cartilage

521. Which of the following statement is false about osteochondromatosis:

A. Usually affects long bones, but can also occur in skull and pelvis
B. Usual site is metaphyseal region
C. Also known as multiple exostoses, diaphyseal aclasia
D. It does not interfere with general body stature

522. Muffucci syndrome:

A. Multiple enchondromatosis with hemangiomas
B. Multiple osteochondromatosis with hemangiomas
C. Multiple osteochondromas
D. Multiple Giant cell tumor

523. Most common tumor in bones of hand:

A. Exostosis
B. Giant cell tumor
C. Enchondroma
D. Synovial sarcoma

524. Identify the lesion in the X-ray:

A. Chondroblastoma
B. Osteoclastoma
C. ABC
D. Eosinophilic granuloma

525. Dense calcification is found in:

A. Osteosarcoma
B. Chondroblastoma
C. Synovial sarcoma
D. Osteoblastoma

526. Characteristic radiological feature of fibrous dysplasia is:

A. Cortical thickening
B. Cortical calcification
C. Ground glass appearance
D. Bone enlargement

527. True about Ameloblastoma:

A. Cystic lesion
B. Rapidly growing
C. Malignant disease
D. MC site is tibia

528. A 33-year-old man presented with a slowly progressive swelling in the middle 1/3rd of his right tibia. X-rays examination revealed multiple sharply demarcated radiolucent lesions separated by areas of dense and sclerotic bone. Microscopic examination of a biopsy specimen revealed island of epithelial cells in a fibrous stroma. Which of the following is the most probable diagnosis?

A. Adamantinoma
B. Osteofibrous dysplasia
C. Osteosarcoma
D. Fibrous cortical defect

529. X-ray proximal femur in a patient with pain hip. The deformity shown is:

A. Blade of grass deformity
B. Shepherd crook deformity
C. Chicken wire appearance
D. Corduroy appearance

530. Musculoskeletal abnormalities in neurofibromatosis is:

A. Hypertrophy of limb
B. Scoliosis
C. Pseudo arthrosis
D. All of the above

531. Striated Vertebra are seen in:

A. Metastasis
B. Tuberculosis
C. Hemangioma
D. Osteoblastoma

517. c	518. b	519. c	520. d	521. d	522. a	523. c	524. a	525. b	526. c	527. a
528. a	529. b	530. d	531. c							

532. Osteoid osteoma consists of:

A. Osteoblasts
B. Osteoclasts
C. Both of the above
D. None of the above

533. A patient presents with pain in the thigh, relieved by aspirin. X- ray shows a radiolucent mass surrounded by sclerosis. Diagnosis is:

A. Osteoma
B. Osteoid osteoma
C. Osteoblastoma
D. Osteoclastoma

533. A. Osteoid osteoma

Clinical picture with night pain relieved with aspirin, and xray sign is diagnostic of osteoid osteoma.

534. Tumor with maximum bone matrix:

A. Osteoid osteoma
B. Chondrosarcoma
C. Enchondroma
D. None

535. Calcification in Osteosarcoma is due to presence:

A. Osteoid matrix
B. Osteoblasts
C. High calcium levels in serum
D. High calcitonin

536. The following reaction is associated with which tumor?

A. Osteosarcoma
B. Chondroblastoma
C. Ewing's
D. Codman's tumor

537. In osteogenic sarcoma predominant histological finding is:

A. Giant cells
B. Osteoid forming tumor cells
C. Fibroblastic proliferation
D. Chondroblasts

538. Children with germline retinoblastoma are more likely to develop other primary malignancies in their later lifetime course. Which of the following can occur in such patients?

A. Osteosarcoma of lower limbs and soft tissue sarcoma
B. Thyroid carcinoma
C. Seminoma
D. Squamous cell carcinoma

539. Radiation induced tumor:

A. Osteosarcoma
B. Ewing's sarcoma
C. Multiple myeloma
D. chondrosarcoma

540. 'T' -10 Protocol' for treatment of Osteosarcoma includes all of the following, except:

A. High dose methotrexate
B. Bleomycin, Cyclophosphamide Doxorubicin (BCD)
C. Vincristine
D. Etoposide

541. All of the following investigations are needed for the diagnosis of Osteosarcoma, except:

A. MRI of femur
B. Bone marrow biopsy
C. Bone scan
D. CT chest

542. A 7-year-old boy presents with swelling and pain over tibia. On X-ray there is periosteal reaction in diaphysis. Probable diagnosis is:

A. Osteomyelitis
B. Chondroblastoma
C. Ewing's Sarcoma
D. Osteosarcoma

543. Poor prognostic sign for Ewing's sarcoma is:

A. Fever
B. Age, 12 years
C. Grade
D. Females

544. 1st decade most common bone tumor:

A. Ewing's sarcoma
B. Osteosarcoma
C. Multiple myeloma
D. Metastasis

545. A 15-year-old boy is injured while playing cricket. Xrays of the leg rule out a possible fracture. The radiologist reports the boy has an evidence of aggressive bone tumor with both bone destruction and soft tissue mass. The bone biopsy reveals a bone cancer with neural differentiation. Which of the following is the most likely diagnosis?

A. Chondroblastoma
B. Ewing's sarcoma
C. Neuroblastoma
D. Osteosarcoma

546. Commonest site of occurrence of chondrosarcoma is:

A. Pelvis
B. Femur
C. Ribs
D. Proximal tibia

547. Tumor with calcification is seen in:

A. Unicameral bone cyst
B. Chondroblastoma
C. Osteoclastoma
D. Chondrosarcoma

532. c	533. b	534. a	535. a	536. a	537. b	538. a	539. a	540. d	541. b	542. c
543. a	544. a	545. b	546. a	547. d						

548. A 7-year-old boy with h/o trauma 2 months back now presents with fever and acute pain over thigh. On X-ray femoral shaft shows lesions with multiple laminated periosteal reaction next line of management:

A. CRP measurement
B. Core biopsy
C. Tc99 MDP scan
D. MRI

549. Physaliferous cells are seen in:

A. Phyllodes tumor
B. Chordoma
C. Meningioma
D. Pheochromocytoma

550. A patient with pain in back. Lab investigation shows elevated ESR. X-ray skull shows multiple punched out lytic lesions. Most important Investigation to be done is:

A. Serum acid phosphatase
B. CT head with contrast
C. Whole body sacn
D. Serum electrophoresis

551. Most common malignancy that metastasizes to the spine is

A. Lung
B. Prostate
C. Breast
D. Thyroid

552. All of the following statements about synovial cell sarcoma are correct except

A. Occurs more often at extra articular sites
B. Originates from synovial lining
C. Usually seen in people under 50 years age
D. Knee is the most common site

553. Generally radiotherapy should not be used for treating benign conditions, the only possible exception being

A. Chondromyxoid fibroma
B. Extensive pigmented vilonodular synovitis
C. Benign fibrous histiocytoma
D. Desmoplastic fibroma so extensive that it cannot be surgically excised

554. Pigmented villo-nodular synovitis most commonly occurs at

A. Knee
B. Hip
C. Shoulder
D. Elbow

555. Metastasis are least common in

A. Vertebra
B. Pelvis
C. Proximal parts of long bones of the upper limb
D. Small bones of the hand

556. A 60-year-old male has bone pain, vertebral collapse and pathological fracture in pelvis. The most probable diagnosis is

A. Multiple myeloma
B. TB
C. Hamangioma of bone
D. Secondaries

557. After radical resection of chordoma, which radiation therapy is best ?

A. Photons
B. Neutrons
C. Protons
D. Electrons

558. 25 years old male having pain and deformity of the tibia. What is the most probable diagnosis?

A. Ewings sarcoma
B. Chronic osteomyelitis
C. Osteosarcoma
D. Stress fracture

548. d	549. b	550. d	551. c	552. b	553. b	554. a	555. d	556. d	557. c	558. b

502. C. Giant cell tumor

Osteosarcoma is a metaphyseal tm & Ewings sarcoma is a diaphyseal tm.

503. B. Epiphyseometaphyseal

- Epiphyseometaphyseal > epiphyseal

504. B. Squamous cell carcinoma

Squamous cell carcinoma is the M/C tumour of hand, but when question is asked M/C tumour of hand bone, than answer becomes enchondroma.

505. B. Chondroblastoma – Soap bubble appearance

Soap bubble appearance is seen in GCT not Chondroblastoma.

506. A. Neuroblastoma

- M/C site of primary in secondary bone tumour-
  - Male- prostate>lung
  - Female- Breast>lung
  - Children- Neuroblastoma
  - If primary unknown – M/C is Lung>Kidney
  - Overall M/C – Breast>prostate>lung>Kidney>thyroid

507. B. Chordoma

Chordoma is a low grade malignant tumour of notochordal remnant.

508. C. Medullary cavity

It is a small round blue cell tm of PNET origin arising from endothelial cells in the bone marrow affecting the diaphysis of long bone

509. C. Aneurysmal bone cyst

Xray is classical of ABC,metaphyseal eccentric, lytic lesion, ballooned out cortex with septation. In SBC, its centric without any septations.

510. C. Treated by simple curettage

Treatment is extended curettage and bone grafting, not simple curettage.

511. A. Simple bone cyst

Its a feature of SBC not ABC, as there is no septation in SBC, when cortex breaks off, it falls off in cavity giving the xray appearance.

512. B. Aneurysmal bone cyst

- Posterior element of vertebrae :
  - Expansile & purely lytic : ABC
  - Non – expansile & ossified : Osteoblastoma
- Body of vertebrae : GCT

513. C. Osteoclast gaint cells constitute the proliferative component of the tumor

It is seen in 20-40 years age group, benign but locally aggressive with uncertain origin (Monocyte macrophage lineage). Although benign, rarely it can have lung metastasis.

514. A. GCT

Xray is s/o of GCT, eccentric expansile lytic lesion,just below subchondral bone (soap bubble appearance, knee is the M/C site of GCT. SBC / ABC are metaphyseal lesion.

515. B. Mononuclear cells

GCT is a benign tumour, but locally aggressive with uncertain origin (Monocyte macrophage lineage).

516. B. Non- Ossifying fibroma

- Non- Ossifying fibroma is a relatively better answer here, as GCT has no matrix calcification, while all other options presents with matrix calcification.
- Giant cell variants – FAN OUCH
  - Fibrous dysplasia
  - ABC
  - Non ossifying fibroma
  - Osteitis fibrosa cystica
  - Unicarmel bone cyst
  - Chondromyxoid fibroma
  - Hyper PTH

517. C. Osteosarcoma

- Osteosarcoma is extremely rare in small bones of hand and feet and does not contain giant cells.

518. B. Excision and bone grafting

Diagnosis here is - GCT. Treatment of choice of GCT at lower end radius is - Excision and bone grafting (sandwich technique).

519. C. Osteochondroma

- M/C primary benign bone tm- osteochondroma/ exostosis (not a true benign tm).
- M/C TRUE primary benign bone tm – Osteoid osteoma
- Enchondroma is the M/C bone tumour of hand.

520. D. Thickness of cartilage

>2cm thickness of cartilage is significant of malignant degeneration in osteochondroma.

521. D. It does not interfere with general body stature

Osteochondromatosis means multiple osteochondromas/ diaphyseal aclasia and osteochondroma's are known to cause growth disturbances.

522. A. Multiple enchondromatosis with hemangiomas

Maffucci's syndrome- Multiple enchondroma, subcutaneous haemangioma and phleboliths.

523. C. Enchondroma

Squamous cell carcinoma is the M/C tumour of hand, but when question is asked M/C tumour of hand bone, than answer becomes enchondroma.

524. A. Chondroblastoma

- Epiphyseal lytic lesion before fusion of epiphysis is Chondroblastoma.
- GCT is also epiphyseal, but that's after closure of physis. Before physeal closure i.e children, Osteoclastoma/GCT is metaphyseal.

525. B. Chondroblastoma

- Cartilageneous lesion presents with stippled calcification and among the given options only chondroblastoma is such tumour.

526. C. Ground glass appearance

- Xray of fibrous dysplasia - well defined lesion k/a ground glass appearance/smoky milky appearance(due to loss of trabecular pattern), with a sclerotic rim k/a "rind sign".

527. A. Cystic lesion

Ameloblastoma (benigh) is a separate entity from adamantinoma (Malignant), M/C site is mandible and xray shows soap bubble appearance.

528. A. Adamantinoma

Adamantinoma is sowly growing, malignat tumour, /C site is tibial diaphysis and biopsy shows epithelial cells in a fibrous stroma, hallmark of diagnosis.

529. B. Shepherd crook deformity

E. Xray is s/o Shepherd crook deformity seen in fibrous dysplasia. Chicken wire appearance is a biopsy appearance seen in chondroblastoma, Corduroy appearance is seen in spine in hemangioma.

530. D. All of the above

All the mentioned options are seen as skeletal deformities in neurofibromatosis.

531. C. Hemangioma

Striated Vertebra (Corduroy appearance) is seen in hemangioma.

532. C. Both of the above

Radiolucent nidus is hallmark of osteoid osteoma, and is made of fibrovascular stroma, surrounded by thick sclerotic bone (it contains both osteoblastic and clastic cells).

533. B. Osteoid osteoma

Clinical picture with night pain relieved with aspirin, and xray sign is diagnostic of osteoid osteoma.

534. A. Osteoid osteoma

Osteosaecoma has maximum bone matrix followed by osteoid osteoma.

535. A. Osteoid matrix

536. A. Osteosarcoma

Metaphyseal tumour with sunray appearance is diagnostic of osteosarcoma. Ewings is diaphyseal and chondroblastoma has popcorn calcification.

537. B. Osteoid forming tumor cells

Tumour can be –

- Osteosclerotic osteoblastic
- Osteolytic or Chondroblastic as the tm cells are pleuripotent.
- Mixed (M/C) fibroblastic But the predominant among this is, the Osteoid forming tumor cells.

538. A. Osteosarcoma of lower limbs and soft tissue sarcoma

Patients of retinoblastoma has high risk of developing osteosarcoma in later life.

539. A. Osteosarcoma

It is the M/C radiation induced tm and occur at unusual sites like skull,clavicle, spine, ribs,etc. It results 10-15 years after radiation exposure

540. D. Etoposide

'T' -10 Protocol' containing the following drugs-

- High dose MTx (HDMTX) with citrovorum factor rescue.
- BCD- Bleomycin, Cyclophosphamide, Dactinomycin.
- Doxorubicin.

541. B. Bone marrow biopsy

- Biopsy always remains the gold standard investigation for neoplasic lesions, in osteosarcoma biopsy is taken from the leading edge of the lesion, not from marrow.

542. C. Ewing's Sarcoma

- Both osteomyelitis and Ewings seems to be answer here, osteomyelitis starts in metaphysis and very rarely/lately involve diaphysis, while Ewings sarcoma site of origin is diaphysis.

543. A. fever

Prognosis - worst prognostic factor is the presence of distant metastasis. Systemic s/s, increased counts, old age and male sex is also a/w poor prognosis. However histological grade is of no prognostic value, as all Ewing's sarcoma tm are considered to be of high grade.

544. A. Ewing's sarcoma

- Ewings sarcoma – 5-15years age group.
- Osteosarcoma – bimodal : 1°- 10-20 years
  any age group is possible 2°- 40-60 years
- Multiple myeloma- >50 years

545. B. Ewing's sarcoma

- Peripheral nerectodermal tumors (PNET) that share a common t (11:22) and round cells, differing only in their degree of neural differentiation, Ewing's sarcoma is poorly differentiated whereas PNET exhibits definite neural differentiation.

546. A. Pelvis

Flat bones (pelvis) is the M/C site of chondrosarcoma.

547. D. Chondrosarcoma

- Cartilageneous tumors are preferred answer in matrix calcification and malignant > bening tumor shows matrix calcification.

548. D. MRI

- Diagnosis here is "Ewing's sarcoma" and next best investigation is MRI. Biopsy remains the gold standard, but before biopsy all non-invasive investigation should be done.

549. B. Chordoma

Physaliferous cells are pathognomic of chordoma.

550. D. Serum electrophoresis

Clinical diagnosis is of multiple myeloma and Serum electrophoresis is the best investigation for the same.

551. C. Breast

- Male- prostate>lung
- Female- Breast>lung
- Overall M/C – Breast>prostate>lung.

552. B. Originates from synovial lining

Synovial cell sarcoma is a mesenchymal malignant tumor that does not have synovial origin despite its name.

553. B. Extensive pigmented vilonodular synovitis

Low dose external beam radiotherapy is the treatment for PVNS.

554. A. Knee

The knee joint is M/C involved f/b hip and shoulder.

555. D. Small bones of the hand

Proximal parts of femur / humerus are the M/C sites of long bone metastasis. Metastasis distal to knee & elbow, i.e acral metastasis is rare and M/C being is tibia and M/c is due to lung tumour. Hand metastasis is the most rare.

556. D. Secondaries

- It could be metastasis, more likely than multiple myeloma, considering the site, the age and the incidence.

557. C. Proton

A type of radiation called proton beam therapy is most often recommended for chordoma patients because it allows delivery of very high doses of radiation to the tumor while minimizing doses to tissues just millimeters away. Another type of particle beam radiation called carbon ion therapy has similar properties to proton beam therapy, but is only available at a small number of centers.

558. B. Chronic osteomyelitis

Ewings and Osteosarcoma would be common between 10-20 years age.

Stress fractures would generally not have a deformity. Considering the age group and site (tibia); chronic osteomyelitis seems to be best pick. However, the information given in the question is too less to conclude.

559. Acute osteomyelitis, earliest bone change can be seen by?

A. PET CT
B. Bone Scan
C. MRI
D. XRAy

560. Stress fracture are diagnosed by?

A. Xray
B. CT
C. MRI
D. Bone scan

561. Which of the following is the IOC for Perthe's disease?

A. MRI
B. CT
C. Xray
D. USG

562. DDH best diagnostic modality is?

A. USG
B. MRI
C. Xray
D. Clinical

563. Periosteal reaction is seen in?

A. Osteomyelitis
B. Syphilis
C. Tumour
D. All

564. A 4 year old child complains of pain and swelling of left tibia. On evaluation patient has high ESR, leucoytosis and xray depicts tibial lesion, best investigation is?

A. Blood C/S
B. MRI
C. Pus C/S
D. Biopsy

565. TB of spine best diagnostic modality is?

A. CT guided biopsy
B. MRI
C. Clinical
D. Xray

566. What is the earliest change of osteomyelitis on xray?

A. Loss of soft tissue planes
B. Sequestrum
C. Periosteal reaction
D. Lytic defects

567. A patient with history of fall on outstretched hand will most probably have injury to which of the marked area in the image?

A. Radius
B. Ulna
C. 3rd metacarpal
D. Capitate

559. c	560. c	561. a	562. b	563. d	564. d	565. a	566. a	567. a

559. B. Bone scan, C. MRI

For OSTEOMYELITIS, MRI gives the earliest diagnosis (within 24 hours) and is the IOC. Bone scan is next in preference to MRI, and can establish the diagnosis within 48-72 hours. Pyogenic osteomyelitis on xrays will show loss of soft tissue planes after 24-48 hours (1st change). Day 7-10 solid periosteal reaction is identified (1st bony change).

560. C. MRI

IOC for U/L is MRI and for B/L is bone scan, bone scan becomes the answer only when B/L is mentioned.

561. A. MRI

Perthes disease is a type of AVN of femur head and is always best/earliest diagnosed by MRI.

562. B. MRI

USG is considered the screening tool for DDH in neonatal age group

In first 6 months of life- USG is the IOC – as femoral head is primarily cartilageneous, so USG picks up well and getting MRI is un-necessary and challenging in this age group.

After 6 months of life – MRI is the IOC as femoral head starts ossifying, USG cannot pick up bone. Xray can still diagnose after 6 months but MRI is the IOC to evaluate complete disease process.

563. All

However periosteal reaction is not seen in Tuberculous infection of bone.

564. D. Biopsy.

D/D : Ewings sarcoma and osteomyelitis, which is BEST diagnosed by biopsy.

565. A. CT guided biopsy

Ttissue diagnosis is always better than any radiological diagnosis. If the que would have been best radiological modality than the answer would have been MRI.

566. A. Loss of soft tissue planes

Pyogenic osteomyelitis on xrays will show loss of soft tissue planes after 24-48 hours (1st change). Day 7-10 solid periosteal reaction is identified (1st bony change).

567. A. radius

Fall on outstretched hand is a common mechanism of distal end radius fracture (Fundamentals of orthopaedics" 2nd edition, pg 329Colles' fracture).

568. A 4-years-child is brought to emergency with complain of severe pain in arm after a fall, immediate X-ray done shows fracture distal radius and ulna. Which of the following term best describes the fracture:

A. Torus
B. Greenstick
C. Barton's
D. Colles

569. What type of fracture is shown on xray :

A. Plastic deformation
B. Green stick fracture
C. Torus fracture
D. Epiphyseal injury

570. Most common bone to be fractured in children is:

A. Distal radius
B. Clavicle
C. Supracondylar
D. Radius/ulna

571. What type of fracture is shown on xray:

A. Plastic deformation
B. Green stick fracture
C. Torus fracture
D. Epiphyseal injury

572. In children best remodeling is seen in fracture with:

A. Angulation in diaphysis
B. Angulation in metaphysis
C. Rotation in diaphysis
D. Rotation in metaphysic

573. Metaphyseal fracture touching physis but not crossing it, comes under which type of Salter-Harris physeal injury?

A. I
B. II
C. III
D. IV

574. Thurston Holland sign is seen in:

A. Type I
B. Type II
C. Types III
D. Type IV

575. Perichondrial ring is:

A. Seen around foramen magnum
B. Seen around epiphyseal plate
C. More prominent in adults
D. Shear strength increases with age

576. An 8-year-old boy with a history of fall from 10 feet height complains of pain in the right ankle. X-ray taken at that time are normal without any fracture line. But after 2 years, he developed a calcaneovalgus deformity. The diagnosis is:

A. Undiagnosed malunited fracture
B. Avascular nercrosis of talus
C. Tibial epiphyseal injury
D. Ligamentous injury of ankle joint

577. All the following are causes of a painful limp except;

A. Slipped femoral epiphysis
B. TB of the hip
C. Perthes disease
D. Infantile Coxa Vara painless.

578. Name the test performed:

A. Galeazzi's sign
B. Barlows test
C. Ortolanis test
D. Trendelenburg test

568. b	569. c	570. d	571. a	572. b	573. b	574. b	575. b	576. c	577. d	578. a

579. The following pelvic X-ray was seen in a patient. All the following signs will be present except:

A. Ortolani
B. Barlow
C. Narath
D. Gaenslen's

580. Pavlik harness is used to treat:

A. Developmental dysplasia of hip
B. Perthe's disease
C. Slipped Capital femoral epiphysis
D. Congenital coxa vara

581. Irregular thigh folds are seen in:

A. Developmental dysplasia of hip
B. Perthe's disease
C. Slipped Capital femoral epiphysis
D. Congenital coxa vara

582. Positive Galeazzi Sign is seen in:

A. Unilateral DDH
B. Bilateral DDH
C. Distal radioulnar dislocation
D. Distal radius fracture

583. Perkin's line on X-ray is used for diagnosis of:

A. Perthe's disease
B. CDH
C. CTEV
D. AVN Hip

584. Ortolani test is positive when the examiner hears the:

A. Clunk of entry on abduction and flexion of hip
B. Clunk of entry on extension and adduction of hip
C. Click of exit on abduction and flexion of hip
D. Click of exit on extension and adduction of hip

585. Which of the following is NOT a feature of DDH?

A. Smaller epiphysis of femoral head
B. Inclination of acetabular roof is increased
C. Shenton's line disrupted
D. Femoral head is anteverted

586. Bachelors' cast is used in:

A. Fracture radius
B. Club foot
C. DDH
D. Fracture calcaneum

587. Primary pathology in CDH:

A. Large head of femur
B. Shallow acetabulum
C. Excessive retroversion
D. Everted limbus

588. Alpha angle in DDH:

A. Decreases
B. Increases
C. Constant
D. Variable

589. what is the diagnosis in a boy of 8 years old presenting with the following xray:

A. Perthes disease
B. SCFE
C. Non union fracture neck of femur
D. Coxa vara

590. An 8-years-old male with painless limp on examination and restricted abduction and internal rotation left hip, probable diagnosis is:

A. Septic arthritis of hip
B. Tuberculosis arthritis of hip
C. Cong dislocation of hip
D. Perthe's disease

591. Perthe's disease is treated by:

A. High dose of calcium with steroids
B. Total hip replacement
C. Supervised containment of femoral head in acetabulum
D. Relieving weight bearing

592. Steels metaphyseal sign is seen in:

A. Perthe's disease
B. SCFE
C. DDH
D. Coxa vara

593. SCFE is most commonly seen in age :

A. 1-5 years
B. 6-10 years
C. 10-15 years
D. 15-20 years

594. 14-year-old boy with 78 kg weight and hypothyroidism developed sudden onset of severe pain and tenderness on left hip as a result of minor fall. Most diagnosis is:

A. Fracture neck femur
B. SCFE
C. Perthes
D. Hip Dislocation

595. Trethowan's sign is seen in:

A. Perthe's disease
B. CDH
C. SCFE
D. Fracture neck femur

579. d	580. a	581. a	582. a	583. b	584. a	585. d	586. c	587. b	588. b	589. a
590. d	591. c	592. b	593. c	594. b	595. c					

596. Treatment of SCFE is:

A. Conservative
B. Surgery by osteotomy
C. Reduction and pinning
D. In situ pinning

597. Commonest presentation of congenital dislocation of knee is:

A. Varus
B. Valgus
C. Flexion
D. Hyperextension

598. A 7-year-old young boy, had fracture of lateral condyle of femur. He developed malunion as the fracture was not reduced anatomically. Malunion will produce:

A. Genu valgum
B. Genu varum
C. Genu recurvatum
D. Dislocation of knee

599. Most common cause of genu valgum in children is:

A. Osteoarthritis
B. Rickets
C. Paget's disease
D. Rheumatoid arthritis

600. A child with 4 years age and angular deformity in knee with the following xray, diagnosis is:

A. Blounts disease
B. Rickets
C. Genu valgum
D. Genu recurvatum

601. which of the following is not a treatment option in this deformity:

A. Medial closing wedge osteotomy
B. Lateral closing wedge osteotomy
C. Full time orthosis
D. Correction of metabolic disorder.

602. Charlie chaplin gait is seen in:

A. CDH
B. Congenital coxa vara
C. Genu valgum
D. External tibial torsion

603. True regarding genu varum is:

A. Orthosis is a must only during weight bearing
B. Orthosis is recommended during day time
C. Orthosis is recommended during night time
D. Orthosis is recommended full time

604. Rocker bottom foot is seen in:

A. Congenital vertical talus
B. Arthrogryposis
C. Holding club foot in too long corrected position
D. All of the above

605. In nail patella syndrome the patella is:

A. Small of absent
B. Larger
C. Triangular
D. Square

606. All of the following are done for management of clubfoot at birth except:

A. Manipulation
B. Serial Casting
C. Recording the deformity to see improvements serially
D. Posteromedial soft tissue release

607. The last deformity to be corrected by Ponsetti method for CTEV is:

A. Heel Varus
B. Equinus
C. Foot Adduction
D. Cavus

608. The typical deformity in CTEV is:

A. Ankle equinus
B. Subtalar inversion
C. Forefoot adduction
D. All the above

609. In correction of CTEV, which one of the following deformities resists?

A. Equinus
B. Varus
C. Adduction
D. Cavus

610. These shoes are used in:



A. CTEV
B. Congenital vertical talus
C. Rocker bottom foot
D. Metatarsus adductus

596. c	597. d	598. a	599. b	600. a	601. a	602. d	603. d	604. d	605. a	606. d
607. b	608. d	609. a	610. a							

611. In neglected cases of CTEV, joint fused are:
A. Calcaneocuboid, talonavicular and talocalcaneal
B. Tibiotalar, calcaneocuboid and talonavicular
C. Ankle joint, calcaneocuboid and talonavicular
D. None of the above

612. Single step Posteromedial release is:
A. Ponsetti
B. Kites
C. Turcos
D. Cincinnati

613. CTEV shoe was designed by:
A. Kites
B. Ponsetti
C. Turcos
D. Thomas

614. A newborn child presents with inverted foot and the dorsum of the foot can not touch the anterior tibia. The most probable diagnosis:
A. Congenital vertical talus
B. Arthrogryposis
C. Congenital talipes equino varus
D. PES planus

615. The ideal treatment of bilateral idiopathic Clubfoot in a newborn is:
A. Manipulation by mother
B. Manipulation and dennis brown splint
C. Manipulationand and casts
D. Surgical release

616. The club foot characteristically involves:
A. Foot and ankle
B. Foot, ankle and leg
C. Foot only
D. Foot, ankle, leg and knee joint

617. Most important pathology in club foot is:
A. Congenital talonavicular dislocation
B. Tightening of Tendoachilles
C. Calcaneal fracture
D. Lateral derangement

618. Triple arthrodesis is NOT done before-skeletal maturation because of:
A. Shortening of foot
B. Recurrence of deformity
C. Inadequate fusion
D. Complete correction not possible

619. 'Pseudoarthrosis' in Triple fusion is seen at the joint of:
A. Calcaneocuboid
B. Calcaneonavicular
C. Naviculocuboid
D. Talonavicular

620. Madelung's deformity involves:
A. Humerus
B. Proximal ulna
C. Distal radius
D. Carpals

621. The following deformity is seen in a child. What is the likely cause?

A. Tibial Hemimelia
B. Fibula Hemimelia
C. Congenital pseudoarthrosis of Tibia
D. Congenital posteromedial angulation of Tibia

622. In some old fractures, cartilaginous tissue forms over the fractured bone ends with a cavity in between containing clear fluid. This condition is called as:
A. Delayed union
B. Slow union
C. Non-union
D. Pseudoarthrosis

623. The characteristic triad of klippel-Feil syndrome includes all the following, except:
A. Short neck
B. Low hair line
C. Limited neck movements
D. Elevated scapula

624. Name of the deformity:

A. Torticollis
B. Fracture clavicle
C. Sprengel deformity
D. Absent Pectoralis major muscle

625. Idiopathic scoliosis can be treated by:
A. Minerva cast
B. Milwaukee brace
C. Crutchfield traction
D. PTB cast

626. Cobb's angle is used to measure the degree:
A. Kyphoscoliosis
B. Angular deformity of the knee
C. Extent of depression in calcaneal fracture
D. Extent of spondylolisthesis

611. a	612. c	613. d	614. c	615. c	616. b	617. a	618. c	619. d	620. c	621. c
622. d	623. d	624. a	625. b	626. a						

627. Risers sign is for:

A. Kyphosis
B. Scoliosis
C. Shortening
D. Lengthening

628. Progression of congenital scoliosis is least likely in which of the following vertebra anomalies:

A. Fully segmented hemivertebra
B. Wedge vertebra
C. Block vertebra
D. Unilateral unsegmented bar with Hemivertebra

629. An 8-year-old child is brought by parents to the casualty with a spiral fracture of Femur and varying degree of Ecchymosis all over body. The etiology is:

A. Hit and run accident
B. Battered baby syndrome
C. Hockey stick injury
D. Osteogenesis imperfect

630. Dactylitis is most commonly associated with ?

A. Sickle cell anaemia
B. Thalessemia
C. Multiple myeloma
D. Haemophilia

627. b	628. c	629. b	630.a

568. B. Greenstick

Torus / buckle fracture – buckling of cortex classically occurring at metaphysio - diaphyseal junction

Greenstick fracture – one cortex breaks and other cortex remains intact.

569. C. Torus fracture .

Plastic deformation – immature (pediatric) bone may undergo plastic deformation before fracture

Torus / buckle fracture – buckling of cortex classically occurring at metaphysio - diaphyseal junction

Greenstick fracture – one cortex breaks and other cortex remains intact.

570. D. Radius/ulna

Supracondylar fracture is the M/C elbow fracture in children, and Radius/ulna fracture is the M/C overall fracture in children.

571. A. Plastic deformation.

Plastic deformation – immature (pediatric) bone may undergo plastic deformation before fracture

Torus / buckle fracture – buckling of cortex classically occurring at metaphysio - diaphyseal junction

Greenstick fracture – one cortex breaks and other cortex remains intact.

572. B. Angulation in metaphysic

Metaphyseal bone has better remodelling than diaphysis and angulation better tolerated than rotation.

573. B. II

574. B. Type II

- In type II Salter Harris fracture, Metaphyseal fragment is known as "Thurston Holland fragment".

575. B. Seen around epiphyseal plate

Physis is connected to the epiphysis and metaphysis by the zone of Ranvier and the perichondral ring of LaCorix.

576. C. Tibial epiphyseal injury

- It is a case of epiphyseal injury, and may not be diagnosed on xray at the time of injury. Later the patient may present with deformity if not diagnosed initially.

577. D. Infantile Coxa Vara

Perthes disease causes painless limp initially, but later may become painful, while Infantile (congenital) coxa vara is characteristically painless.

578. A. Galeazzi's sign.

The test performed is Galleazi test, done to diagnose CDH.

579. D. Gaenslen's Test

Barlow's, Ortolani's & galleazi test are done in CDH, while Gaenslen test is done in Ankylosing spondylitis.

580. A. Developmental dysplasia of hip.

Pavlik harness is the M/C splint used in DDH.

581. A. Developmental dysplasia of hip

Irregular thigh fold is seen in DDH, due to disproportionate limb lengths.

582. A. Unilateral DDH

Galleazi sign is seen in DDH. However it is positive in unilateral case not bilateral, as the basis of test is difference in knee heights due to disproportionate limb lengths.

583. B. CDH

Perkin's line, Hilgenreiner's line are used to diagnose DDH.

584. A. Clunk of entry on abduction and flexion of hip.

Ortolani's test & Barlow's test are used in DDH. Barlow is test for dislocation (Instability) and Ortolani is reducibility of dislocated hip. On abduction and flexion hip redues from dislocated position.

585. D. Femoral head is anteverted

When head remains dislocated, growth of head is hampered resulting in small head and acetabulum undergoes dysplasia resulting in vertical (i.e increased inclination) orientation.

586. C. DDH

Fracture radius – colles cast, club foot – ponsetti's cast, DDH -Bachelor's cast, broomstick cast.

587. B. Shallow acetabulum

In DDH – primary pathology is dysplasia of acetabulum resulting in shallow cup. Other finding is small head, inverted limbs.

588. B. Decreases

Alpha angle decreases and beta angle increases in DDH.

589. A. Perthes disease.

The Xray is classical of Perthes disease. There is AVN with collapse of capital physis of (L) side.

590. D. Perthe's disease.

Perthe's disease is M/C below 10 years age, with painless limp and restricted abduction / IR. In CDH there is no restriction of movement & septic arthritis is painful. TB hip is painless to start with, but once arthritis sets in, it is also painful.

591. C. Supervised containment of femoral head in acetabulum.

Supervised containment of femoral head in acetabulum is the TOC in Perthe's disease, so that acetabulum moulds as per head shape. There is no role of calcium & steroids, THR will not be performed in paediatric age when Perthe's is seen.

592. B. SCFE

Metaphyseal sign of steel is an Xray sign - where there is a crescentic shaped area of increased density due to overlapping of head and neck due to slippage.

593. C. 10-15 years.

1-8 years age – Perthes, 10-12 years age – SCFE.

594. B. SCFE

14 years, obese with endocrinological disturbance – SCFE. # NOF (at this age) & hip dislocation will require major trauma not minor. Perthe's is common in 4-8 years age.

595. C. SCFE

Trethowan sign is seen in SCFE in large slips.

596. C. Reduction and pinning

Slight anatomical reduction followed by fixation is required so as to keep epiphysis, physis and metaphysis in place.

597. D. Hyperextension

Hyperextension is the M/C type of congenital knee dislocation.

598. A. Genu valgum

- 7 year old boy means, growth plate is intact. Now when injury occurs laterally, medial side will grow uninterrupted and will produce valgus deformity, similarly medial injury will produce varus deformity.

599. B. Rickets

M/C cause of genu varum is physiological in toddlers and nutritional rickets after 3 years age. Osteoarthritis causes G. Varum and RA causes G.Valgum. M/C cause of G.valgum is idiopathic > renal osteodystrophy > rickets.

600. A. Blounts disease.

- Note the metaphyseal beaking, characteristic of Blount's disease.

601. A. Medial closing wedge osteotomy.

Medial close wedge osteotomy will further deteriorate this disorder. In medial side open wedge osteotomy can be performed for genu varum.

602. D. external tibial torsion

In externa tibial torsion, patient walk with out-toeing gait, with hip & knee typical of Charlie Chaplin.

603. D. Orthosis is recommended full time

M/C cause of genu varum is rickets and deformity corrects on treatment of rickets. During treatment, full time orthosis (HKAFO) is given to prevent deformity from increasing.

604. D. All of the above

Rocker bottom foot is – convex plantar surface. May be due to vertical/oblique talus (arthrogryposis) or over-corrected CTEV.

605. A. Small or absent

In nail-patella syndrome, patella is either small or absent, not necessarily change of shape.

606. D. Posteromedial soft tissue release

Management of CTEV is by Ponsetti technique, where foot is manipulated, serial cast is applied and records of deformity is maintained for follow up.

607. B. Equinus

Sequence of correction is CAVE – Cavus –adduction – varus – equines.

608. D. All the above

CTEV involves foot,ankle and leg and the deformities are :

- Cavus intertarsal joint (prominent medial longitudinal arch)
- Adduction of forefoot at tarso-metatarsal joint
- Varus/inversion at subtalar joint

CAVE

- Equinus at ankle joint, and
- medial rotation of distal tibia.

609. A. Equinus

Equinus is the last to correct and most troublesome.

610. A. CTEV.

It is foot abdution orthosis (Denis Browne splint) used in CTEV.

611. A. Calcaneocuboid, talonavicular and talocalcaneal

- These three joints are fused and is know as "triple arthrodesis".

612. C. Turcos

Turcos incision is used in PMSTR.

613. D. Thomas

614. C. Congenital talipes equino varus

The test mentioned is dorsiflexion test which can be used as a screening test in newborn children for CTEV.

615. C. Manipulation and casts

Idiopathic club foot is always managed by Ponsetti technique (manipulation and serial casing). However idiopathic clubfoot after 1-2 years age or those secondary to any syndromes, Ponsetti technique alone is not sufficient.

616. B. Foot, ankle and leg

CTEV involves foot,ankle and leg and the deformities are :

- Cavus intertarsal joint (prominent medial longitudinal arch)
- Adduction of forefoot at tarso-metatarsal joint
- Varus/inversion at subtalar joint CAVE

- Equinus at ankle joint
- Medial rotation of distal tibia.

617. A. Congenital talonavicular dislocation

Talus is most severely affected and talo- navicular joint complex/dislocation is the corner stone of the deformity.

618. C. Inadequate fusion

Before skeletal maturation, bones are not completely ossified and fusion is not possible.

619. D. Talonavicular

- Pseudoarthrosis is the most common complication and occurs at talonavicular joint.

620. C. Distal radius

Madelung's deformity involves distal radius and closest d/D is malunited distal radius fracture.

621. C. Congenital pseudoarthrosis of Tibia

Although clinical details is not provided, Congenital pseudoarthrosis of Tibia is the best diagnosis here. It occurs mostly unilateral, distal third tibia, bowing antero-laterally. However, fibula hemimelia is the closest D/D presenting with bowing antero-medially.

622. D. Pseudoarthrosis

Other three mentioned options are types of union/ non-union, but when a pseudocavity is formed in the fractured site, the condition is k/a pseudoarthrosis.

623. D. Elevated scapula

Triad of klippel-Feil syndrome : short neck, low hair line and restriction of neck motion.

Sprengel shoulder has a common association with klippel Feil Syndrome, but its not a part of the triad.

624. A. Torticollis.

Image is classical of torticollis. Neck is bent to one side

625. B. Milwaukee brace

Crutchfield is used in cervical spine traction, PTB cast in tibia fracture. Minerva cast was used in scoliosis but not used now-a-days.

626. A. Kyphoscoliosis

Cobb's Angle - It measures severity of scoliosis (from upper and lower border of vertebrae) and thus guides in management of scoliosis.

627. B. Scoliosis

Risser Sign -The **Risser sign** is an indirect measure of skeletal maturity, whereby the ossification stage of the iliac apophysis is used to judge the ossification of the spinal vertebrae, used in scoliosis.

628. C. Block vertebra

Unilateral unsegmented bar with Hemivertebra has highest chances of progression. Block vertebrae has laest chances.

629. B. Battered baby syndrome

Child with Spiral fracture (significant of assault/ twist injury) with ecchymosis all over the body point towards Battered baby syndrome.

630. A. Sickle cell anaemia

One of the earliest clinical manifestations is dactylitis, presenting as early as six months of age, and may occur in children with sickle-cell trait.